

**AMERICAN ASSOCIATION OF CLINICAL ENDOCRINOLOGISTS,  
AMERICAN COLLEGE OF ENDOCRINOLOGY, AND  
ASSOCIAZIONE MEDICI ENDOCRINOLOGI MEDICAL GUIDELINES FOR  
CLINICAL PRACTICE FOR THE DIAGNOSIS AND MANAGEMENT OF  
THYROID NODULES – 2016 UPDATE**

**APPENDIX**

*Hossein Gharib, MD, MACP, MACE<sup>1</sup>, Co-Chair; Enrico Papini, MD, FACE<sup>2</sup>, Co-Chair;  
Jeffrey R. Garber, MD, FACP, FACE<sup>3</sup>; Daniel S. Duick, MD, FACP, FACE<sup>4</sup>;  
R. Mack Harrell, MD, FACP, FACE, ECNU<sup>5</sup>; Laszlo Hegedüs, MD<sup>6</sup>; Ralf Paschke, MD<sup>7</sup>;  
Roberto Valcavi, MD, FACE<sup>8</sup>; Paolo Vitti, MD<sup>9</sup>;  
on behalf of the AACE/ACE/AME Task Force on Thyroid Nodules\**

*American Association of Clinical Endocrinologists (AACE), American College of Endocrinology (ACE) and Associazione Medici Endocrinologi (AME) Medical Guidelines for Clinical Practice for the Diagnosis and Management of Thyroid Nodules are systematically developed statements to assist health care professionals in medical decision making for specific clinical conditions. Most of the content herein is based on literature reviews. In areas of uncertainty, professional judgment was applied.*

*The first edition of the AACE/ACE/AME Guidelines for the Diagnosis and Management of Thyroid Nodules was published in 2006 after extensive review of the literature by representatives of endocrinologists, endocrine surgeons, and thyroid pathologists and with accurate external refereeing. These guidelines were updated in 2010 by a task-force group representing experts from the same scientific societies and from the European Thyroid Association on the basis of advances in diagnosis and management of thyroid nodules. The Task Force now editing this third edition of the guidelines on behalf of AACE/ACE/AME includes new contributors and referees. This updated edition incorporates recent scientific evidence, includes the use of new diagnostic tools and treatments, and addresses avoiding unnecessary diagnostic procedures and risk of medical or surgical overtreatment. The importance of patient information and participation in clinical decision making and the role of a multidisciplinary approach to thyroid nodular disease are fully considered.*

*These guidelines are a working document that reflects the state of the field at the time of publication. Because rapid changes in this area are expected, periodic revision is inevitable. We encourage medical professionals to use this information in conjunction with their best clinical judgment. Any decision by practitioners to apply these guidelines must be made in light of local resources and individual patient circumstances and preference.*



**Abbreviations:**

**AACE** = American Association of Clinical Endocrinologists; **ACE** = American College of Endocrinology; **AFTN** = autonomously functioning thyroid nodule; **AME** = Associazione Medici Endocrinologi; **AUS/FLUS** = follicular lesion/atypia of undetermined significance; **BEL** = best evidence level; **BSRTC** = Bethesda System for Reporting Thyroid Cytopathology; **BTA** = British Thyroid Association; **CEUS** = contrast medium-enhanced ultrasonography; **CNB** = core-needle biopsy; **CT** = computed tomography; **<sup>18</sup>FDG** = 2-fluorine-18 2-fluoro-2-deoxy-D-glucose; **FDG** = 2-fluoro-2-deoxy-D-glucose; **FNA** = fine-needle aspiration; **FNA-CT** = calcitonin measurement in fine-needle aspiration washout; **FNA-PTH** = parathyroid hormone measurement in fine-needle aspiration washout; **FNA-Tg** = thyroglobulin measurement in fine-needle aspiration washout; **FN/SFN** = pure follicular patterned lesion, suggesting a follicular neoplasm; **FTC** = follicular thyroid cancer; **FT<sub>3</sub>** = free triiodothyronine; **FT<sub>4</sub>** = free thyroxine; **GEC** = gene expression classifier; **IMAX** = maximum intensity of peak; **LTA** = laser thermal ablation; **LT<sub>4</sub>** = levothyroxine; **MEN2** = multiple endocrine neoplasia type 2; **MeSH** = Medical Subject Headings; **MNG** = multinodular goiter; **MRI** = magnetic resonance imaging; **MTC** = medullary thyroid carcinoma; **NPV** = negative predictive value; **OR** = odds ratio; **PEI** = percutaneous ethanol

injection; **PET** = positron emission tomography; **PPV** = positive predictive value; **PTC** = papillary thyroid carcinoma; **PTH** = parathyroid hormone; **PTMC** = papillary thyroid microcarcinoma; **RFA** = radiofrequency ablation; **rhTSH** = recombinant human thyrotropin (thyroid-stimulating hormone); **<sup>99m</sup>Tc MIBI** = technetium sestamibi; **Tg** = thyroglobulin; **Thy 3** = neoplasm possible-atypia nondiagnostic; **TIRADS** = Thyroid Imaging Reporting and Data System; **TPOAb** = anti-thyroid peroxidase antibody; **TRAb** = antithyrotropin-receptor antibody; **TSH** = thyroid-stimulating hormone (thyrotropin); **UK-RCPATH** = UK Royal College of Pathologists; **US** = ultrasonography, ultrasonographic.

**ABSTRACT**

Thyroid nodules are detected in up to 50 to 60% of healthy subjects. Most nodules do not cause clinically significant symptoms, and as a result, the main challenge in their management is to rule out malignancy, with ultrasonography (US) and fine-needle aspiration (FNA) biopsy serving as diagnostic cornerstones. The key issues discussed in these guidelines are as follows: (1) US-based categorization of the malignancy risk and indications for US-guided FNA (henceforth, FNA), (2) cytologic classification of FNA samples, (3) the roles of immunocytochemistry and molecular testing applied to thyroid FNA, (4) therapeutic options, and (5) follow-up strategy. Thyroid nodule management during pregnancy and in children are also addressed. On the basis of US features, thyroid nodules may be categorized into 3 groups: low-, intermediate- and high-malignancy risk. FNA should be considered for nodules ≤10 mm diameter only when suspicious US signs are present, while nodules ≤5 mm should be monitored rather than biopsied. A classification scheme of 5 categories (nondiagnostic, benign, indeterminate, suspicious for malignancy, or malignant) is recommended for the cytologic report. Indeterminate lesions are further subdivided into 2 subclasses to more accurately stratify the risk of malignancy. At present, no single cytochemical or genetic marker can definitely rule out malignancy in indeterminate nodules. Nevertheless, these tools should be considered together with clinical data, US signs, elastographic pattern, or results of other imaging techniques to improve the management of these lesions. Most thyroid nodules do not require any treatment, and levothyroxine (LT<sub>4</sub>) suppressive therapy is not recommended. Percutaneous ethanol injection (PEI) should be the first-line treatment option for relapsing, benign cystic lesions, while US-guided thermal ablation treatments may be considered for solid or mixed symptomatic benign thyroid nodules. Surgery remains the treatment of choice for malignant or suspicious nodules. The present document updates previous guidelines released in 2006 and 2010 by the American Association

From <sup>1</sup>Professor of Medicine, Mayo Clinic College of Medicine, Past President, American Association of Clinical Endocrinologists, Past President, American Thyroid Association; <sup>2</sup>Director, Department of Endocrinology and Metabolism, Regina Apostolorum Hospital, Via San Francesco 50, 00041, Albano, Rome (Italy); <sup>3</sup>Endocrine Division, Harvard Vanguard Medical Associates, Boston, Massachusetts, Division of Endocrinology, Beth Israel Deaconess Medical Center, Boston, Massachusetts; <sup>4</sup>Endocrinology Associates, PA, Professor of Medicine, College of Medicine, University of Arizona (Phoenix and Tucson Campuses); <sup>5</sup>Co-Director Memorial Center for Integrative Endocrine Surgery; <sup>6</sup>Professor of Endocrinology at the University of Southern Denmark, Consultant Physician at the Department of Endocrinology and Metabolism at Odense University Hospital; <sup>7</sup>Professor and Head Division of Endocrinology and Metabolism, Department of Oncology & Arnie Charbonneau Cancer Institute, Cummings School of Medicine, University of Calgary, Richmond Road Diagnosis and Treatment Centre (RRDTC), 1820 Richmond RD SW, Calgary AB T2T5C7; <sup>8</sup>Director of the Endocrinology Unit, Centro Palmer, Reggio Emilia, Via Fratelli Cervi 75/b, Italy; <sup>9</sup>Professor, University of Pisa, Section of Endocrinology, Department of Clinical and Experimental Medicine.

\*A complete list of the AACE/ACE/AME Thyroid Nodule Task Force can be found in the Acknowledgements section of this publication.

Address correspondence to American Association of Clinical Endocrinologists, 245 Riverside Ave, Suite 200, Jacksonville, FL 32202.

E-mail: publications@aace.com. DOI:10.4158/EP161208.GL

To purchase reprints of this article, please visit: [www.aace.com/reprints](http://www.aace.com/reprints).

Copyright © 2016 AACE.

of Clinical Endocrinologists (AACE) and Associazione Medici Endocrinologi (AME).

## I. INTRODUCTION

This document was prepared as a collaborative effort between the American Association of Clinical Endocrinologists (AACE), American College of Endocrinology (ACE) and Associazione Medici Endocrinologi (AME). These guidelines cover diagnostic and therapeutic aspects of thyroid nodular disease but not thyroid cancer management. Suggestions for thyroid nodule management during pregnancy and childhood are also presented herein (see Table of Contents). The AACE protocol for standardized production of clinical practice guidelines was followed to rate the evidence level of each reference and to link the guidelines to the strength of recommendations (see Methods).

The basis of thyroid nodule management is the use of high-resolution ultrasonography (US), sensitive thyrotropin (TSH, formerly thyroid-stimulating hormone) assay, and fine-needle aspiration (FNA) biopsy, together with clinical findings. Thyroid scintigraphy is not necessary for diagnosis in most cases; however, it may be warranted in patients with a low serum TSH value or a multinodular gland to detect functional autonomy, most common in iodine-deficient areas. Measurement of serum TSH is the best initial laboratory test of thyroid function and should be followed by measurement of free thyroxine (FT<sub>4</sub>) and free triiodothyronine (FT<sub>3</sub>) when the TSH value is decreased, and measurement of thyroid peroxidase antibodies (TPOAbs) and FT<sub>4</sub> when the TSH value is above the reference range. A single, nonstimulated serum calcitonin measurement should be performed only when medullary thyroid carcinoma (MTC) is suspected due to FNA results or history.

Thyroid nodules are a common finding because they are detected in up to 50 to 60% of healthy people. In most cases, they appear in euthyroid persons and cause neither compressive symptoms nor cosmetic concerns. Accordingly, the main clinical challenge in the treatment of these patients is to rule out malignancy. Most patients with thyroid nodules are asymptomatic, but the absence of symptoms does not rule out malignancy. Thus, clinical and US risk factors for malignant disease should always be reviewed. All patients with a palpable thyroid nodule or clinical risk factors should undergo US examination.

Thyroid FNA should always be performed under US guidance because it makes the procedure safer, more reliable, and more accurate. In light of the low clinical risk, nodules <5 mm should always be monitored with US rather than biopsied. FNA should be considered for nodules with a major diameter ≤5-10 mm only when suspicious US signs are present (high US risk thyroid lesions) in

association with pathologic lymph nodes or extrathyroidal spread. FNA is also appropriate in cases where the patient has a personal or family history of thyroid cancer or of coexistent suspicious clinical or imaging findings. FNA should be performed on nodules >10 mm that are devoid of suspicious US and/or clinical findings yet do not show a definite benign appearance (intermediate US risk thyroid lesions). Finally, FNA should be performed on spongiform, isohyperechoic, or predominantly (>50%) cystic nodules in the absence of suspicious US findings (low US risk thyroid lesions) only when nodules are ≥20 mm or progressively increasing in size. Nodules that are functioning on scintigraphy and devoid of suspicious US features can be excluded from FNA.

A classification scheme of 5 cytologic diagnostic categories and 2 subcategories is recommended for the cytologic report: nondiagnostic, benign, indeterminate, suspicious for malignancy, or malignant. Indeterminate lesions are further subdivided into 2 subclasses with significantly different estimated risks of cancer, to better stratify the risk of malignancy associated with the “indeterminate” nodules.

Nondiagnostic aspirates composed of pure colloid and obtained from a nodule that is completely cystic on US should be labeled as compatible with a colloid cyst and require clinical and US follow-up. Solid, persistently nondiagnostic nodules may be considered for US-guided core-needle biopsy (CNB) for microhistologic assessment. Alternatively, those with clearly favorable clinical and US findings can be monitored with close surveillance, whereas suspicious lesions should be surgically resected.

Nodules with benign cytologic characteristics should undergo clinical and US follow-up. A repeat FNA should be performed in the case of suspicious clinical and/or US findings or with substantial and progressive nodule enlargement, defined as a volume increase >50% (greater than the interobserver coefficient of variation). Most patients with benign thyroid nodules do not require any treatment; levothyroxine (LT<sub>4</sub>) suppressive therapy is not recommended in euthyroid patients. In iodine-deficient geographic regions, iodine supplementation is recommended, and a trial of non-TSH-suppressive treatment with LT<sub>4</sub> may be considered in young patients with a small nodular goiter. Symptomatic goiters, whether euthyroid or hyperthyroid, may be treated surgically or with radioiodine. Percutaneous ethanol injection (PEI) is the first-line treatment of relapsing benign cystic thyroid lesions. In patients with solid or complex, symptomatic or progressively enlarging benign thyroid nodules, US-guided thermal ablation treatments may effectively control nodule growth and local symptoms.

Malignant or suspicious nodules should be treated surgically. Preoperative evaluation with US, FNA, and, if needed, further imaging techniques, is recommended for appropriate surgical planning.

In nodules with indeterminate cytologic results, no single cytochemical or genetic marker is specific or sensitive enough to rule out malignancy with certainty. However, the use of immunohistochemical and molecular markers may be considered together with the cytologic subcategories and data from US, elastography, or other imaging techniques to obtain additional information for management of these patients.

In selected cases (e.g., neck masses suspicious for lymph node metastasis from thyroid cancer, enlarged parathyroid glands), hormone measurement in the needle wash-outs increases FNA diagnostic accuracy.

These guidelines provide information to improve the management of patients with thyroid nodules. These recommendations must always take into account available local expertise, the clinical setting, and patient preference.

## II. METHODS

### Development and Use of the Guidelines:

#### Methods of Bibliographic Research

We searched for primary evidence to support the current guidelines by using a “clinical question” method. Each topic covered by the guidelines was translated to a related question. Accordingly, the bibliographic research was conducted by selecting studies able to yield a methodologically reliable answer to each question. The first step was to select pertinent published reports. The U.S. National Library of Medicine Medical Subject Headings (MeSH) database was used as a terminologic filter. Appropriate MeSH terms were identified, and care was taken to select them on a sensitive rather than a specific basis. The MeSH terms and their proper combination enabled us to retrieve the reports pertinent to a specific issue.

The second step was to select relevant published studies. Beginning with the pertinent reports indexed with the appropriate MeSH terminologic filters, we applied the PubMed clinical queries methodologic filters. The clinical queries were grouped into 4 categories: diagnosis, etiology, prognosis, and therapy. For each clinical question, a proper complex search string is available (364 [EL 4], 365 [EL 4]). From the combination of terminologic (MeSH terms) and methodologic filters (clinical queries), we selected the relevant studies that provided a reliable answer to the question.

After the relevant published studies had been retrieved, the bibliographic research continued by looking for further evidence cited in the bibliography of each report and by following the Related Articles link listed next to each item in MEDLINE. Meta-analyses were searched both in MEDLINE and the Cochrane Library. Three methods were used to search for meta-analyses in MEDLINE:

- Selection of “Meta-Analysis” from the “Publication Type” menu on the “Limits” tab of the PubMed main page.

- Application of function “Find Systematic Reviews” on the “Clinical Queries” PubMed page.
- Use of Hunt and McKibbin’s complex string for systematic reviews (228 [EL 3]): AND (meta-analysis [pt] OR meta-anal\* [tw] OR metaanal\* [tw]) OR (quantitative\* review\* [tw] OR quantitative\* overview\* [tw]) OR (systematic\* review\* [tw] OR systematic\* overview\* [tw]) OR (methodologic\* review\* [tw] OR methodologic\* overview\* [tw]) OR (review [pt] AND medline [tw]).

The Cochrane Library was browsed by entering free terms in the search window. Guidelines were searched in MEDLINE and several guidelines databases. Two methods were used to search for guidelines in MEDLINE:

- Selection of “Practice Guidelines” from the “Publication Type” menu on the “Limits” tab of the PubMed main page.
- Use of the following GIMBE-Gruppo Italiano Medicina Basata sulle Evidenze complex string for the guidelines: “guideline” [pt] OR “practice guideline” [pt] OR “health planning guidelines” [mh] OR “consensus development conference” [pt] OR “consensus development conference, nih” [pt] OR “consensus development conferences” [mh] OR “consensus development conferences, nih” [mh] OR “guidelines” [mh] OR “practice guidelines” [mh] OR (consensus [ti] AND statement [ti]).

Guidelines were searched in the following databases: National Guideline Clearinghouse (U.S.); Agency for Healthcare Research and Quality (U.S.); Canadian Medical Association—Clinical Practice Guidelines; Canadian Task Force on Preventive Health Care; National Institutes of Health—National Heart, Lung, and Blood Institute (U.S.); National Health Service Research and Development Health Technology Assessment Programme (UK); National Institute of Clinical Excellence (UK); New Zealand Guidelines Group; PRODIGY Guidance—National Health Service (UK); and the Scottish Intercollegiate Guidelines Network.

### Levels of Evidence and Grading of Recommendations

The AACE protocol for standardized production of clinical practice guidelines was followed to rate the evidence level of each reference on a scale of 1 to 4 and to link the guidelines to the strength of recommendations on the basis of grade designations A (action based on strong evidence) through D (action not based on any evidence or not recommended) (Table 1) (366 [EL 4-guidelines]). The BEL, corresponding to the best conclusive evidence found, accompanies the recommendation grade (367 [EL 4]). All recommendations resulted from a consensus among the

**Table 1**  
**Strength-of-Evidence Scales Reported in the Medical Literature<sup>a</sup>**

Level of evidence	Description	
1	Well-controlled, generalizable, randomized trials	
	Adequately powered, well-controlled multicenter trials	
	Large meta-analyses with quality ratings	
	All-or-none evidence	
2	Randomized controlled trials with limited body of data	
	Well-conducted prospective cohort studies	
	Well-conducted meta-analyses of cohort studies	
3	Methodologically flawed randomized clinical trials	
	Observational studies	
	Case series or case reports	
4	Conflicting evidence, with weight of evidence supporting the recommendation	
	Expert consensus	
	Expert opinion based on experience	
	“Theory-driven conclusions” Unproven claims	
Level of evidence	Description	Action
A	>1 Conclusive level 1 publications demonstrating benefit >> risk Action based on strong evidence	Action recommended for indications reflected by published reports
		Action can be used with other conventional therapy or as first-line therapy
B	No conclusive level 1 publication	Action recommended for indications reflected by the published reports
	≥1 Conclusive level 2 publications demonstrating benefit >> risk	Use if the patient declines or does not respond to conventional therapy; must monitor for adverse effects
		Action based on intermediate evidence Can be recommended as “second-line” therapy
C	No conclusive level 1 or 2 publications	Action recommended for indications reflected by the published reports
	≥1 Conclusive level 3 publication demonstrating benefit >> risk	Use when the patient declines or does not respond to conventional therapy, provided there are no important adverse effects;
	<b>Or</b> No conclusive risk at all and no benefit at all	
D		“No objection” to recommending their use
		<b>Or</b>
		“No objection” to continuing their use Action based on weak evidence
D	No conclusive level 1, 2, or 3 publication demonstrating benefit >> risk	Not recommended Patient is advised to discontinue use
	Conclusive level 1, 2, or 3 publication demonstrating risk >> benefit	Action not based on any evidence

<sup>a</sup> Adapted from Mechanick et al (366) and Mechanick et al (367). Used with permission.

AACE and AME primary writers and were influenced by input from the Task Force members and reviewers.

Some recommendations were upgraded or downgraded on the basis of expert opinion. In these cases, subjective factors such as clinical experience, cost, risk, and regional availability of specific technologies and expertise took priority over the reported BEL.

### III. EXECUTIVE SUMMARY

#### A. SECTIONS

To guide readers, the 2016 Clinical Practice Guidelines for the Diagnosis and Management of Thyroid Nodules are divided into the following sections:

- The Scope of the Problem
- Clinical Evaluation and Diagnosis
- Thyroid Ultrasonography and Other Diagnostic Imaging Studies
- Thyroid Biopsy
- Laboratory Evaluation
- Radionuclide Scanning
- Management and Therapy
- Thyroid Nodules during Pregnancy
- Management of Thyroid Nodules in Children

Readers are referred to the Appendix for more detail and supporting evidence for each section.

#### B. SUMMARY OF RECOMMENDATIONS

##### 1. Thyroid Nodules: The Scope of the Problem

- These guidelines are designed to optimize the current clinical practice in the diagnosis and management of thyroid nodules and nodular goiters.
- The recommendations should always be applied considering clinical setting, local medical expertise, available technical resources, and patient preferences [BEL 3, GRADE B].

##### 2. Clinical Evaluation and Diagnosis

###### 2.1. History

- We recommend that the following data be recorded:
  - Age
  - Personal or family history of thyroid disease or cancer
  - Previous head or neck irradiation
  - Rate of neck mass growth
  - Anterior neck pain
  - Dysphonia, dysphagia, or dyspnea
  - Symptoms of hyper- or hypothyroidism
  - Use of iodine-containing drugs or supplements [BEL 2, GRADE A]
- Most nodules are asymptomatic and benign, but the absence of symptoms does not rule out malignancy [BEL 2, GRADE A].

###### 2.2. Physical Examination

- We recommend a careful, focused examination of the thyroid gland and cervical lymph nodes [BEL 3, GRADE B].
- Record the following data:
  - Thyroid volume and consistency
  - Location, consistency, size, and number of nodule(s)
  - Neck tenderness or pain
  - Cervical adenopathy [BEL 3, GRADE B]
- The risk of cancer is not substantially different in patients with a solitary nodule versus patients with a multinodular goiter (MNG) [BEL 2, GRADE B].

#### 3. Thyroid Ultrasonography and Other Diagnostic Imaging Studies

##### 3.1. When to Perform Thyroid Ultrasound

- Ultrasound (US) evaluation is recommended for patients who are at risk for thyroid malignancy (see Table 3); have palpable thyroid nodules or goiter, or have neck lymphadenopathy suggestive of a malignant lesion [BEL 2, GRADE A].
- US evaluation is not recommended as a screening test for the general population or patients with a normal thyroid on palpation and a low clinical risk of thyroid disease [BEL 4, GRADE C].

##### 3.2. How to Describe US Findings

We recommend the following approach to describe US findings:

- Focus the US report on stratification for risk of malignancy
- Describe position, size, shape, margins, content, echogenic pattern, and vascular features of the nodule(s)
- For multiple nodules, detail the nodule(s) bearing the US characteristics associated with malignancy rather than describing the largest (dominant) nodule.
- For suspicious regional neck lymph nodes, describe the cervical compartment, number, shape, size, margins, content, echogenic pattern, presence of hilum, and vascular features [BEL 2, GRADE A].

##### 3.3. US Rating of the Risk of Malignancy

- In thyroid US reports, add to the description of US features a rating that stratifies thyroid lesions on the basis of their risk of malignancy to reliably communicate the expected risk of cancer (see Table 4) [BEL 3, GRADE B].

##### 3.4. US Classification Systems

The following US rating system of the risk of malignancy is suggested see Table 5 and Fig. 1 and 2):

- **Class 1. Low-risk thyroid lesion.**
  - Mostly cystic (>50%) nodules with reverberating artifacts that are not associated with suspicious US signs
  - Isoechoic spongiform nodules confluent or with regular halo
  - The expected risk of malignancy is about 1%.
- **Class 2. Intermediate-risk thyroid lesion.**
  - Slightly hypoechoic nodules (cf. surrounding thyroid tissue) and isoechoic nodules with ovoid-to-round shape and smooth or ill-defined margins.
  - Intranodular vascularization, elevated stiffness at elastography, macro- or continuous rim calcifications, or hyperechoic spots of uncertain significance may be present.
  - The expected risk of malignancy is 5 to 15%.
- **Class 3. High-risk thyroid lesion.** Nodules with at least 1 of the following suspicious features:
  - Marked hypoechogenicity (cf. prethyroid muscles)
  - Spiculated or microlobulated margins
  - Microcalcifications
  - Taller-than-wide shape
  - Evidence of extrathyroidal growth or pathologic adenopathy
  - The expected risk of malignancy is 50 to 90% in accordance with the presence of 1 or more suspicious findings [BEL 4, GRADE C].

### 3.5. Indications for US-Guided Fine-Needle Aspiration

#### 3.5.1. How to select nodule(s) for US-guided FNA

- In the selection of nodules for US-guided fine-needle aspiration (FNA), consider a balance between the risk of a potentially delayed diagnosis and that of superfluous diagnostic procedures or surgery (see Fig. 1) [BEL 4, GRADE C].
- In light of the low clinical risk, nodules with a major diameter <5 mm should be monitored, rather than biopsied, with US, irrespective of their sonographic appearance [BEL 3, GRADE B].
- In nodules with a major diameter 5-10 mm that are associated with suspicious US signs (high US risk thyroid lesions), consider either FNA sampling or watchful waiting on the basis of the clinical setting and patient preference [BEL 3, GRADE B]. Specifically, US-guided FNA is recommended for the following nodules:
  - Subcapsular or paratracheal lesions
  - Suspicious lymph nodes or extrathyroid spread
  - Positive personal or family history of thyroid cancer

- Coexistent suspicious clinical findings (e.g., dysphonia) [BEL 2, GRADE A]
- FNA is recommended for the following:
  - High US risk thyroid lesions ≥10 mm
  - Intermediate US risk thyroid lesions >20 mm
  - Low US risk thyroid lesions only when >20 mm and increasing in size or associated with a risk history and before thyroid surgery or minimally invasive ablation therapy [BEL 2, GRADE A]
- FNA is not recommended for nodules that are functional on scintigraphy (see difference in recommendations for children; Section 8.4.) [BEL 2, GRADE B].

#### 3.5.2. FNA of multinodular glands and lymph nodes

- We do not recommend the biopsy of more than 2 nodules in the same patient when the nodules are selected on the basis of the previously described criteria [BEL 3, GRADE C].
- If a radioisotope scan is available, we recommend not biopsying hot areas [BEL 2, GRADE B].
- In the presence of suspicious cervical lymphadenopathy, we recommend FNA for cytologic assessment of both the lymph node and the suspicious nodule(s) [BEL 2, GRADE A].
- We recommend the determination of thyroglobulin (Tg) or calcitonin, according to clinical indications, on FNA washout of suspicious lymph nodes [BEL 2, GRADE A].

#### 3.5.3. FNA of complex thyroid nodule(s)

- We recommend sampling the solid component of the lesion through FNA biopsy [BEL 3, GRADE B].
- Preferentially sample the vascularized areas of complex lesions [BEL 4, GRADE C].
- Submit both the FNA specimen and the drained fluid for cytologic examination [BEL 2, GRADE A].

#### 3.5.4. FNA of thyroid incidentalomas

- Manage thyroid incidentalomas according to the previously described criteria for nodule diagnosis [BEL 2, GRADE A].
- Perform US evaluation of incidentalomas detected by computed tomography (CT) or magnetic resonance imaging (MRI) before consideration of FNA biopsy [BEL 2, GRADE A].
- We recommend that thyroid incidentalomas detected by positron emission tomography (PET) with <sup>18</sup>F-fluorodeoxyglucose (focal uptake, in particular) should undergo US evaluation and FNA because of the high risk of malignancy [BEL 2, GRADE A].

### 3.6. Other Diagnostic Imaging Techniques

- MRI and CT are not recommended for routine thyroid nodule evaluation [BEL 2, GRADE A].
- Consider MRI and CT for assessment of size, airway compression, substernal extension of a nodular goiter, or presence of pathologic lymph nodes in cervical regions not visualized by US [BEL 3, GRADE B].
- PET/CT may provide additional information about the risk of malignancy in thyroid nodules with indeterminate cytologic results. Because of the insufficient diagnostic accuracy, high cost, and limited accessibility, we do not suggest its routine use as a diagnostic tool [BEL 3, GRADE B].
- Consider PET/CT only for the preoperative staging of malignant nodules with aggressive features [BEL 3, GRADE B].

### 3.7. Other US Techniques

- Elastography provides information about nodule stiffness that is complementary to grayscale findings [BEL 2, GRADE B].
- Elastography should not be used as a substitute for grayscale US examination but as a complementary tool in nodules with indeterminate US or cytologic findings [BEL 2, GRADE A].
- Perform FNA in nodules with increased stiffness [BEL 2, GRADE B].
- Use of US contrast medium is not recommended for the diagnostic evaluation of thyroid nodules [BEL 3, GRADE C].
- Use of US contrast medium is recommended only for the assessment of the area of tissue ablation induced by minimally invasive techniques [BEL 3, GRADE B].

## 4. Thyroid Biopsy

### 4.1. Thyroid FNA

- Combine clinical and US evaluation and, when appropriate, FNA results in the clinical management of thyroid nodules [BEL 2, GRADE A].
- Always perform thyroid FNA because cytologic diagnoses are more reliable and the nondiagnostic rates are lower than with palpation-guided FNA (see Table 6) [BEL 2, GRADE A].

#### 4.1.1. Requisition form

- Include all relevant clinical and US information [BEL 4, GRADE C].
- Include a rating of the US risk of malignancy based on an acknowledged US classification system [BEL 3, GRADE B].

- Use the following 3 US rating categories: high risk, intermediate risk, and low risk [BEL 4, GRADE C].
- Clearly state the sampling site and technique and the number of submitted slides and/or other sampled specimens [BEL 3, GRADE B].

#### 4.1.2. Cytologic report

- Include a brief description of cytologic findings and, when possible, a conclusive cytologic diagnosis [BEL 2, GRADE A].
- Identify the cytologic result by adding a rating of the risk of malignancy based on an established classification system for thyroid cytology [BEL 2, GRADE A].

### 4.2. Cytologic Diagnosis

- Define FNA results as either diagnostic (satisfactory) or nondiagnostic (unsatisfactory) [BEL 3, GRADE B].
- As a general rule, define the cytologic specimen as *diagnostic* when the sample contains a minimum of 6 groups of well-preserved thyroid epithelial cells consisting of at least 10 cells per group [BEL 3, GRADE B].
- Classify cytologic specimens characterized by marked atypia as *suspicious*, even in the absence of the required number of follicular cells for adequacy [BEL 3, GRADE B].
- Five diagnostic classes with a subdivision of indeterminate samples in 2 subclasses are recommended for cytologic reports (see Table 2) [BEL 2, GRADE A].
- Use the following reporting system for thyroid cytologic characteristics:

#### **Thyroid 1. Nondiagnostic**

- Inadequate or insufficient to make a diagnosis
- Cystic: insufficient but consistent with a benign cystic lesion

#### **Thyroid 2. Benign**

#### **Thyroid 3. Indeterminate**

- Atypia or follicular lesion of undetermined significance (or a similar subclass in comparable cytologic classification systems [see Table 2])
- Follicular neoplasm or lesion suspicious for follicular neoplasm (or similar subclass in comparable cytologic classification systems [see Table 2])

#### **Thyroid 4. Suspicious for malignancy**

#### **Thyroid 5. Malignant** [BEL 2, GRADE A]

### 4.3. FNA Pitfalls

- To decrease the risk of misleading cytologic results, consider the following:
  - False-negative results are usually due to inappropriate target selection or inadequate sampling.



- False-positive results are usually due to specimens with suspicious, but nondiagnostic, findings [BEL 4, GRADE C].
  - For indeterminate cytologic findings, consider a second opinion from an experienced cytopathologist because some of these cases may, in high-volume thyroid cytopathology units, be reassessed as definitely benign or malignant [BEL 3, GRADE C].
  - To decrease the risk of false-negative results, we recommend the following:
    - Routine use of FNA
    - Aspiration of at least 2 sites within the nodule
    - For multiple nodules, prioritize nodules to be sampled according to US findings.
    - For cystic lesions, sample solid or vascularized areas with FNA and submit cyst fluid for cytologic examination.
    - Review of the slides with an experienced cytopathologist
    - Follow-up on benign nodule(s)
    - Repeat FNA in benign nodules with suspicious clinical or US findings.
    - In large-sized thyroid lesions, sample peripheral and, possibly, solid areas to avoid fluid or necrotic zones [BEL 3, GRADE B].
- 4.3.1. *Thyroglobulin and Hormone Measurement on FNA washout*
- Measurement of Tg, calcitonin, or parathyroid hormone (PTH) levels on FNA washout of suspicious thyroid lesions or lymph nodes is recommended when clinically appropriate [BEL 2, GRADE A].
  - Each center should determine its own reference range for hormone measurement from FNA washout samples [BEL 3, GRADE B].
- 4.4. *Core-Needle Biopsy*
- Consider the use of US-guided core-needle biopsy (CNB) in solid thyroid nodules with persistently inadequate FNA cytologic findings [BEL 3, GRADE C].
  - Because of the limited evidence and lack of established reporting systems, we do not recommend either in favor of or against the use of CNB in nodules with indeterminate cytologic results [BEL 4, GRADE D].
- 4.5. *Immunocytochemistry*
- Immunocytochemistry is suggested for lesions that are suspected of nonfollicular origin (e.g., parathyroid gland, medullary thyroid carcinoma, lymphoma, metastases from other organs) [BEL 3, GRADE B].
- 4.6. *Molecular Testing*
- 4.6.1. *When molecular testing should be considered*
- To complement not replace cytologic evaluation [BEL 2, GRADE A]
  - The results are expected to influence clinical management [BEL 2, GRADE A].
  - As a general rule, not recommended in nodules with established benign or malignant cytologic characteristics [BEL 2, GRADE A]
- 4.6.2. *Molecular testing for cytologically indeterminate nodules*
- Cytopathology expertise, patient characteristics, and prevalence of malignancy within the population being tested impact the negative predictive values (NPVs) and positive

**Table 2**  
**Comparison of the Italian AME Consensus, BSRTC, and UK-RCPPath Systems for Classification and Reporting of Thyroid Cytologic Results**

Italian Consensus, 2014	BSRTC	UK-RCPPath
TIR 1. Nondiagnostic	I. Nondiagnostic	Thy 1. Nondiagnostic
TIR 1c. Nondiagnostic cystic	I. Cystic fluid only	Thy 1c. Unsatisfactory, consistent with cyst
TIR 2. Nonmalignant	II. Benign	Thy 2/Thy 2c. Nonneoplastic
TIR 3A. Low-risk indeterminate lesion	III. AUS/FLUS atypia or follicular lesion of undetermined significance	Thy 3a. Neoplasm possible: atypia/nondiagnostic
TIR 3B. High-risk indeterminate lesion	IV. Follicular neoplasm or suspicious for follicular neoplasm	Thy 3f. Neoplasm possible: suggestive of follicular neoplasm
TIR 4. Suspicious for malignancy	V. Suspicious for malignancy	Thy 4. Suspicious for malignancy
TIR 5. Malignant	VI. Malignant	Thy 5. Malignant

Abbreviations: AME = Associazione Medici Endocrinologi; AUS/FLUS = follicular lesion/atypia of undetermined significance; BSRTC = Bethesda System for Reporting Thyroid Cytopathology; TIR = Thyroid Imaging Reporting; Thy = thyroid; UK-RCPPath = UK Royal College of Pathologists.

predictive values (PPVs) for molecular testing [BEL 3, GRADE B].

- Consider the detection of *BRAF* and *RET/PTC* and, possibly, *PAX8/PPARG* and *RAS* mutations if such detection is available [BEL 2, GRADE B].
- Because of the insufficient evidence and the limited follow-up, we do not recommend either in favor of or against the use of gene expression classifiers (GECs) for cytologically indeterminate nodules [BEL 2, GRADE B].

#### 4.6.3. Role of molecular testing for deciding the extent of surgery

- Currently, with the exception of mutations such as BRAFV600E that have a PPV approaching 100% for papillary thyroid carcinoma (PTC), evidence is insufficient to recommend in favor of or against the use of mutation testing as a guide to determine the extent of surgery [BEL 2, GRADE A].

#### 4.6.4. How should patients with nodules that are negative at mutation testing be monitored?

- Since the false-negative rate for indeterminate nodules is 5 to 6% and the experience and follow-up for mutation-negative nodules or nodules classified as *benign* by a GEC are still insufficient, close follow-up is recommended [BEL 3, GRADE B].

## 5. Laboratory Evaluation

### 5.1. Thyroid Hormones

- Always measure serum thyrotropin (TSH) [BEL 1, GRADE A].
- If TSH level is decreased, measure free thyroxine (FT<sub>4</sub>) plus total or free triiodothyronine (FT<sub>3</sub>); if TSH level is increased, measure FT<sub>4</sub> and antithyroid peroxidase antibody (TPOAb) [BEL 2, GRADE A].
- Test for Tg antibody in patients with US or clinical findings suggestive of chronic lymphocytic thyroiditis, when serum levels of TPOAbs are normal [BEL 3, GRADE B].
- Assessment of serum Tg is not recommended in the diagnosis of thyroid nodules [BEL 2, GRADE A].
- In patients undergoing surgery for cancer, a preoperative serum Tg measurement may be considered [BEL 4, GRADE D].
- Perform TSH receptor antibody (TRAb) measurement for patients with TSH levels below the reference range when Graves disease is suspected [BEL 3, GRADE B].

### 5.2. Calcitonin

- We do not recommend either in favor of or against the routine determination of serum

calcitonin level in the evaluation of thyroid nodules [BEL 3, GRADE D].

- Determine serum calcitonin in thyroid nodules with suspicious US findings or indeterminate cytologic findings [BEL 3, GRADE B].
- Obtain serum calcitonin level for patients with a family history or clinical suspicion of medullary thyroid carcinoma (MTC) or multiple endocrine neoplasia type 2 (MEN2) [BEL 2, GRADE A].
  - If the basal calcitonin level is increased, repeat the test in the absence of possible modifiers [BEL 2, GRADE A].
  - If an elevated (<100 pg/mL) calcitonin level is confirmed, perform a calcium stimulation test to increase the diagnostic accuracy [BEL 3, GRADE C].
- Due to a lack of availability, pentagastrin stimulation is no longer recommended [BEL 3, GRADE C].

### 5.3. Other Tests

- Measure serum calcium and PTH when a nodular lesion is suggestive of parathyroid adenoma [BEL 3, GRADE B].

## 6. Radionuclide Scanning

### 6.1. When to Perform Thyroid Scintigraphy

- In a thyroid nodule or MNG, when the TSH level is below the lower limit of the reference range, or when ectopic thyroid tissue or a retrosternal goiter is suspected [BEL 2, GRADE A].
- In iodine-deficient regions, to exclude autonomy of a thyroid nodule or MNG even when the TSH level is low-normal (e.g., 0.5-1.0 mIU/L). [BEL 3, GRADE B].
- Independent of TSH level and whether in iodine-deficient or -sufficient regions, we recommend scintigraphy to evaluate eligibility for radioiodine therapy [BEL 2, GRADE B].

### 6.2. How to Perform Thyroid Scintigraphy

- Use of <sup>123</sup>I, <sup>99m</sup>TcO<sub>4</sub><sup>-</sup> (sodium pertechnetate), or technetium sestamibi can be considered for thyroid scintigraphy [BEL 3, GRADE C].
- Sodium iodide <sup>131</sup>I thyroid uptake is not recommended for routine diagnostic use unless low-uptake thyrotoxicosis is suspected [BEL 3, GRADE B].

## 7. Management and Therapy (See Fig. 1-3)

### 7.1. Nodules Nondiagnostic by FNA

- If initial FNA is nondiagnostic and the nodule is solid on US, we recommend repeating the FNA with US guidance [BEL 2, GRADE A].

- When cytologic results by FNA are repeatedly inadequate in solid nodules, consider performing a US-guided CNB [BEL 3, GRADE C].
- Consider surgery for persistently nondiagnostic solid nodules. Follow-up may be considered in a minority of solid nodules with clearly favorable clinical and US features [BEL 3, GRADE C].
- Follow-up clinically and with US persistently the nondiagnostic cystic or predominantly (> 50%) cystic, nodules with no suspicious clinical or US features [BEL 3, GRADE C].

## 7.2. Nodules Benign by FNA

### 7.2.1. Follow-up

- Perform clinical follow-up of FNA benign nodules, unless symptomatic [BEL 2, GRADE A].
- Consider a repeat clinical and US examination and TSH measurement in approximately 12 months in accordance with clinical setting [BEL 3, GRADE B].
- If nodules are unchanged at the first US control, repeat the US follow-up after 24 months [BEL 3, GRADE C].
- In asymptomatic nodules with a repeated benign cytology and no suspicious clinical or US features, routine follow-up may be avoided [BEL 3, GRADE D].
- In nodules with benign cytology but suspicious clinical or US features, a repeat FNA is recommended [BEL 3, GRADE B].
- In nodules with an increase >50% in volume or that become symptomatic, we recommend repeat FNA [BEL 2, GRADE A].

### 7.2.2. Medical treatment for benign nodules

- Levothyroxine (LT<sub>4</sub>) suppressive therapy is not recommended [BEL 1, GRADE A].
- In geographic areas with mild iodine deficiency, iodine supplementation and/or TSH nonsuppressive LT<sub>4</sub> treatment may be considered for young patients with a small nodular goiter and high-normal TSH levels [BEL 2, GRADE B].
- LT<sub>4</sub> replacement is recommended for young patients with subclinical hypothyroidism and due to autoimmune thyroiditis [BEL 2, GRADE A].
- LT<sub>4</sub> therapy is not recommended for preventing recurrence after lobectomy when serum TSH stays in the normal range [BEL 2, GRADE A].

### 7.2.3. Surgical indications for benign nodules

- Consider surgery when local pressure symptoms are present and clearly associated with the nodule(s) or in the case of appearance of suspicious US features, despite benign FNA findings [BEL 2, GRADE B].

- The preferred extent of resection for benign uninodular goiter is lobectomy plus isthmectomy. For MNG, it is (near) total thyroidectomy [BEL 2, GRADE A].

### 7.2.4. Percutaneous ethanol injection for benign nodules

- Percutaneous ethanol injection (PEI) is a safe and effective outpatient therapy for thyroid cysts and complex nodules with a large fluid component [BEL 1, GRADE A].
- Carefully sample the solid component of complex lesions before performing PEI [BEL 3, GRADE B].
- PEI is recommended as the first-line treatment for relapsing benign cystic lesions [BEL 1, GRADE A].
- PEI is not recommended for solid nodules, whether hyperfunctioning or not, or for MNGs. This procedure may be considered for hot nodules having compressive symptoms only when other treatment modalities are not accessible [BEL 2, GRADE A].

### 7.2.5. Image-guided thermal ablation for benign nodules

- Consider laser or radiofrequency ablation for the treatment of solid or complex thyroid nodules that progressively enlarge, are symptomatic or cause cosmetic concern [BEL 2, GRADE C].
- Repeat FNA for cytologic confirmation before thermal ablation treatment [BEL 3, GRADE B].

### 7.2.6. Radioiodine therapy

#### 7.2.6.1. When and how to perform radioiodine therapy

- Consider radioiodine therapy for hyperfunctioning and/or symptomatic goiter, especially for patients with previous thyroid surgery or at surgical risk and in those who decline surgery [BEL 2, GRADE A].
- Perform FNA before radioiodine therapy on coexistent cold nodules, per the recommendations given for nontoxic MNG [BEL 3, GRADE B].
- Avoid the use of iodine contrast agents or iodinated drugs before radioiodine administration [BEL 2, GRADE A].
- If possible, withdraw antithyroid drugs 4 to 7 days before treatment and consider resumption 1 week after radioiodine therapy [BEL 2, GRADE B].

#### 7.2.6.2. Contraindications

- Radioiodine is contraindicated in pregnant and breastfeeding subjects [BEL 2, GRADE A].

**12 Thyroid Nodule Management, *Endocr Pract.* 2016;22(Suppl 1)**

- In females of childbearing potential, perform a pregnancy test before administration of radioiodine [BEL 2, GRADE A].
- 7.2.6.3. Follow-up after radioiodine therapy
- Regular thyroid function monitoring is recommended [BEL 2, GRADE A].
  - Consider repeat treatment after 3 to 6 months in the case of persistent or recurrent hyperthyroidism or inadequate size reduction [BEL 3, GRADE B].

7.3. Indeterminate Lesions

7.3.1. *Management*

- Base the management of indeterminate thyroid nodules on their cytologic subclassification, clinical data, and US features [BEL 2, GRADE A].
- Consider elastography for additional information [BEL 2, GRADE B].
- Consider the available technical resources and patient preferences [BEL 4, GRADE D].

7.3.2. *Subclasses of indeterminate cytologic findings*

- Distinguish on the basis of morphologic alterations and background component, 2 cytologic subclasses at expected different risk of malignancy, according to the British Thyroid Association System for Reporting Cytopathology classification or to comparable cytologic classification systems (see Table 3).

7.3.2.1. Management of low-risk indeterminate lesions (AUS/FLUS, Thy 3a, TIR 3A category nodules)

- Consider conservative management in the case of favorable clinical criteria, such as personal or family history, lesion size, and low-risk US and elastography features [BEL 3, GRADE C].
- Repeat FNA for further cytologic assessment and review samples with an experienced cytopathologist [BEL 3, GRADE B].
- CNB may be considered to provide micro-histologic information, but routine use is

not currently recommended because its role in indeterminate lesions is still unsettled [BEL 3, GRADE C].

- We do not recommend either in favor or against the determination of molecular markers for routine use in this category (see Section 7.6.3.3.) [BEL 3, GRADE D].

7.3.2.2. Management of high-risk indeterminate lesions (FN/SFN, Thy 3f, or TIR 3B category nodules)

- Surgery is recommended for most thyroid lesions in this category [BEL 2, GRADE A].
- Thyroid lobectomy plus isthmectomy is recommended; total thyroidectomy may be performed, depending on clinical setting, the coexistence of contralateral lobe thyroid nodules, and patient preference [BEL 2, GRADE A].
- Frozen sections are usually not useful [BEL 4, GRADE D].
- Consider close clinical follow-up in a minority of cases with favorable clinical and US features, but only after multidisciplinary consultation and discussion of treatment options with the patient [BEL 4, GRADE C].

7.4. Management of FNA-Suspicious Nodules

- Surgical treatment is recommended [BEL 1, GRADE A].
- Repeat FNA in cases with inadequate cellularity or those that need additional techniques for a better characterization [BEL 3, GRADE B].
- Intraoperative frozen sections may be considered [BEL 3, GRADE B].

7.5. Nodules Malignant at FNA

7.5.1. *Management*

- In the case of differentiated thyroid carcinoma, surgical treatment is recommended [BEL 1, GRADE A].

**Table 3. Features Suggesting Increased Risk of Malignant Potential**

• History of head and neck irradiation
• Family history of medullary thyroid carcinoma, multiple endocrine neoplasia type 2, or papillary thyroid carcinoma
• Age <14 or >70 years
• Male sex
• Growth of the nodule
• Firm or hard nodule consistency
• Cervical adenopathy
• Fixed nodule
• Persistent dysphonia, dysphagia, or dyspnea

- For anaplastic thyroid carcinoma, metastatic lesions, and thyroid lymphoma, further diagnostic work-up is recommended before surgical intervention [BEL 2, GRADE A].

7.5.2. *Preoperative evaluation*

- Review US and cytologic results with the patient, discuss treatment options, and obtain consultation with a surgeon experienced in endocrine surgery [BEL 2, GRADE A].
- US examination of the neck, FNA biopsy of any concomitant suspicious nodule or lymph node, and vocal cord assessment with laryngoscopy are recommended before surgery [BEL 2, GRADE A].
- In the case of suspicious US features, confirm the metastatic nature of a lymph node with measurement of Tg or calcitonin in the wash-out of the FNA needle [BEL 2, GRADE A].
- Consider the use of MRI, CT, and/or <sup>18</sup>F-FDG PET/CT in selected cases with aggressive features for more accurate preoperative staging [BEL 3, GRADE B].

**8. Thyroid Nodules During Pregnancy**

8.1. *Clinical Approach*

- Manage thyroid nodules for pregnant subjects in the same way as for nonpregnant subjects [BEL 2, GRADE A].
- When suspicious clinical or US findings are present, we recommend FNA since cytologic diagnostic criteria are not substantially influenced by pregnancy [BEL 2, GRADE A].
- Use of radioactive agents for diagnostic, as well as therapeutic, purposes is contraindicated [BEL 2, GRADE A].
- In the case of subnormal TSH levels during the second half of pregnancy, postpone radionuclide thyroid scan until after delivery and cessation of breastfeeding [BEL 2, GRADE A].
- During pregnancy, TSH-suppressive LT<sub>4</sub> therapy for thyroid nodules or goiter is not recommended [BEL 3, GRADE B]. Iodine supplementation should be used in pregnant females living in iodine-deficient regions [BEL 2, GRADE A].
- For thyroid nodules that grow substantially or become symptomatic during pregnancy, follow-up with US examination is recommended, and if appropriate, FNA is also recommended [BEL 2, GRADE A].
- If FNA shows indeterminate cytologic findings, we recommend US monitoring and postponing surgery until after delivery [BEL 3, GRADE B].

8.2. *Management of FNA-Malignant Nodules*

- When thyroid malignancy is diagnosed during the first or second trimester, thyroidectomy should be performed during the second trimester [BEL 3, GRADE B].
- For females with clinical or US evidence of extracapsular growth or lymph node metastases, consider surgical treatment during the second trimester of pregnancy [BEL 3, GRADE B].
- Women without evidence of aggressive thyroid cancer may be reassured that surgical treatment performed soon after delivery is unlikely to adversely affect the prognosis. Close clinical and US monitoring is recommended [BEL 3, GRADE B].
- When thyroid malignancy is diagnosed during the third trimester, in absence of aggressive findings, surgical treatment can be deferred until the immediate postpartum period [BEL 3, GRADE C].
- For patients with suspicious or malignant thyroid nodules in whom surgery is postponed until after delivery, we suggest maintenance of TSH at low-normal levels (e.g., 0.5-1.0 mIU/L) [BEL 3, GRADE B].

**9. Management of Thyroid Nodules in Children**

- Evaluation and management of nodular disease in children are similar to adults [BEL 3, GRADE B].
- Because of a greater prevalence of malignancy in children with thyroid nodules, consider surgical treatment of “cold” as well as hot nodules [BEL 3, GRADE C].

**IV. APPENDIX: EVIDENCE BASE**

**A. APPENDIX: TABLE OF CONTENTS**

**1. Thyroid Nodules: The Scope of the Problem . . . 14**

**2. Clinical Evaluation and Diagnosis . . . . . 15**

2.1. History

2.2. Physical Examination

**3. US and Other Diagnostic Imaging Studies . . . . 16**

3.1. When to Perform Thyroid US

3.2. How to Describe US Findings

3.3. US Rating of the Risk of Malignancy

3.4. US Classification Systems

3.5. Indications for US-Guided FNA

3.5.1. *How to select nodule(s) for US-guided FNA*

3.5.2. *FNA of multinodular glands and lymph nodes*

## 14 Thyroid Nodule Management, *Endocr Pract.* 2016;22(Suppl 1)

3.5.3. FNA of complex thyroid nodule(s)	
3.5.4. FNA of thyroid incidentalomas	
3.6. Other Diagnostic Imaging Techniques	
3.7. Other US Techniques	
<b>4. Thyroid Biopsy . . . . .</b>	<b>28</b>
4.1. Thyroid FNA	
4.1.1. Requisition form	
4.1.2. Cytologic report	
4.2. Cytologic Diagnosis	
4.3. FNA Pitfalls	
4.3.1. Thyroglobulin and hormone measurement on FNA washout	
4.4. Core-Needle Biopsy	
4.5. Immunocytochemistry	
4.6. Molecular Testing	
4.6.1. When molecular testing should be considered	
4.6.2. Molecular testing for cytologically indeterminate nodules	
4.6.3. Role of molecular testing for deciding the extent of surgery	
4.6.4. How should patients with nodules that are negative at mutation testing be monitored?	
<b>5. Laboratory Evaluation . . . . .</b>	<b>34</b>
5.1. Thyroid Hormones	
5.2. Calcitonin	
5.3. Other Tests	
<b>6. Radionuclide Scanning . . . . .</b>	<b>36</b>
6.1. When to Perform Thyroid Scintigraphy	
6.2. How to Perform Thyroid Scintigraphy	
<b>7. Management and Therapy . . . . .</b>	<b>37</b>
7.1. Nodules Nondiagnostic by FNA	
7.2. Nodules Benign by FNA	
7.2.1. Follow-up	
7.2.2. Medical treatment for benign nodules	
7.2.3. Surgical indications for benign nodules	
7.2.4. Percutaneous ethanol injection for benign nodules	
7.2.5. Image-guided thermal ablation for benign nodules	
7.2.6. Radioiodine therapy	
7.2.6.1. Considerations to "When and how to perform radioiodine therapy	
7.2.6.2. Contraindications	
7.2.6.3. Follow-up after radioiodine therapy	
7.3. Indeterminate Lesions	
7.3.1. Management	
7.3.2. Subclasses of indeterminate cytologic findings	
7.3.2.1. Management of low-risk indeterminate lesions (AUS/FLUS, Thy 3a, or TIR 3A category nodules)	

7.3.2.2. Management of high-risk indeterminate nodules (FN/SFN, Thy 3f, or TIR 3B category nodules)	
7.4. Management of FNA-Suspicious Nodules	
7.5. Nodules Found Malignant by FNA	
7.5.1. Management	
7.5.2. Preoperative evaluation	

<b>8. Thyroid Nodules During Pregnancy. . . . .</b>	<b>46</b>
8.1. Clinical Approach	
8.2. Management of FNA-Malignant Nodules	

<b>9. Management of Thyroid Nodules in Children . . . . .</b>	<b>47</b>
---------------------------------------------------------------	-----------

## B. EVIDENCE BASE

### 1. Thyroid Nodules: The Scope of the Problem

Historically, a thyroid nodule has been described as a palpable lump in the thyroid gland. Now, it is more appropriately defined as a distinct lesion that may be differentiated from the surrounding thyroid parenchyma by US examination or other sensitive imaging (1 [EL 4-review]). Hence, clinically detected nodules need confirmation by US or, more rarely, thyroid scintigraphy, computed tomography (CT), or magnetic resonance imaging (MRI) examination (1 [EL 4-review],2 [EL 4-review]).

Thyroid nodules represent a common clinical finding. Whereas studies based on inspection and palpation reported a 3 to 7% prevalence (3 [EL 2]), clinically inapparent thyroid nodules have been detected by US in 20% to as many as 76% of the general population (4 [EL 2], 5 [EL 4], 6 [EL 2]), a prevalence similar to that in autopsy data (7 [EL 3]). Moreover, 20 to 48% of patients with 1 palpable thyroid nodule are found to have additional nodules on US investigation (5 [EL 4]). Thyroid nodules are more common in elderly persons, females, subjects from iodine-deficient geographic areas, and those with a history of radiation exposure (5 [EL 4]). The estimated annual incidence rate of 0.1% in the U.S. indicates that 350,000 new nodules will be discovered in that country this year (5 [EL 4]). Thyroid nodules are frequently detected in the course of a neck imaging study performed for reasons unrelated to thyroid disease (8 [EL 4]). In everyday clinical practice, thyroid incidentalomas are detected in 9.4 to 27.0% of carotid duplex studies (9 [EL 2]), and additional cases from such imaging techniques as CT, MRI, and 2-fluorine-18, 2-fluoro-2-deoxy-D-glucose (<sup>18</sup>FDG) positron emission tomography (PET) (10 [EL 2]). Thus, the widespread use of imaging techniques has generated an epidemic of nonpalpable thyroid nodules, sometimes at the lower limits of sonographic detection (11 [EL 4]). As a consequence, a growing number of asymptomatic thyroid nodules have been subjected to FNA, resulting in a huge increase in the diagnosis and treatment of papillary

thyroid microcarcinomas (PTMCs) (12 [EL 4],13 [EL 2]). The massive increase of thyroid cancer is attributed largely to improved technology and detection of small papillary thyroid carcinoma (PTC) (14 [EL 3]). Overdiagnosis and overtreatment of small PTCs have resulted in a re-evaluation of the management approach to the tumors, with debate on how and when to treat these small, often incidentally discovered lesions (15 [EL 3], 16 [EL 3], 17 [EL 4], 17 [EL 4], 18 [EL 4-review]). It seems most cost-effective to clinically follow small thyroid lesions that are devoid of suspicious US findings and have a low risk of cancer.

### Recommendations

- These guidelines are designed to optimize the current clinical practice in the diagnosis and management of thyroid nodules and nodular goiters.
- The recommendations should always be applied considering clinical setting, local medical expertise, available technical resources, and patient preferences (BEL 4, Grade C).

## 2. Clinical Evaluation and Diagnosis

### 2.1. History

Both benign and malignant disorders can cause thyroid nodules (19 [EL 4]). Hence, the clinical importance of a newly diagnosed thyroid nodule is primarily the exclusion of malignancy (1 [EL 4-review]). However, local symptoms, functional autonomy, and hyperthyroidism are common accompanying problems in iodine-deficient areas (20 [EL 2]).

During examination, patients should be asked about a family history of benign or malignant thyroid disease. Familial medullary thyroid carcinoma (MTC), multiple endocrine neoplasia type 2 (MEN2), familial polyposis coli, Cowden disease, and Gardner syndrome should be carefully considered (18 [EL 4-review],21 [EL 2]). A family history of papillary thyroid tumor only moderately increases the risk of malignancy (22 [EL 2]) but has a greater clinical relevance when at least 2 first-degree relatives have had thyroid carcinoma. Moreover, in nonmedullary thyroid carcinoma, a positive family history may indicate earlier and more severe disease (23 [EL 3]).

Previous disease or treatments involving the neck such as childhood head and neck irradiation moderately increase the risk of malignancy (22 [EL 3]). The rapidity of onset and rate of growth of the neck swelling should be carefully documented. The presence of thyroid nodules during childhood and adolescence should induce caution because the malignancy rate is higher in the young than in adult patients (24 [EL 3]). The risk of thyroid cancer is also higher, even if only slightly in older persons and males (5 [EL 4],21 [EL 2]) (Table 3).

### 2.2. Physical Examination

Most patients with thyroid nodules are asymptomatic or report symptoms that cannot be reliably related to

the nodule (1 [EL 4-review],2 [EL 4-review],3 [EL 2]). In symptomatic patients, a detailed history and complete physical examination may guide the selection of appropriate clinical and laboratory investigations. Slow growth over years may be present in benign nodules (25 [EL 2],26 [EL 3]). Conversely, progressive nodule growth (during weeks or months) deserves attention because this pattern may suggest malignancy. The sudden appearance of a lump in the thyroid region associated with pain is commonly due to hemorrhage in a cystic nodule. However, in patients with progressive and painful enlargement of a thyroid nodule, anaplastic thyroid carcinoma, rare forms of chronic thyroiditis (e.g., Riedel disease), and primary lymphoma of the thyroid should be considered (1 [EL 4-review],2 [EL 4-review]). Coexistence of fever, dysphagia, and malaise with thyroid tenderness is suggestive of subacute thyroiditis (1 [EL 4-review],27 [EL 3]).

Symptoms such as choking sensations, vague cervical tenderness or pain, dysphagia, or hoarseness may be perceived as induced by thyroid disease but are caused by nonthyroid disorders in most subjects. Slow-onset cervical symptoms and signs caused by the compression of vital structures of the neck or upper thoracic cavity usually only occur when thyroid nodules are embedded within large goiters (1 [EL 4-review],2 [EL 4-review]). The symptoms and signs of tracheal compression (cough and dysphonia) may suggest the risk of an underlying malignant lesion; therefore, surgical treatment should be considered in patients with growth of a thyroid mass and vocal cord paresis, even when cytologic results are negative for malignancy (1 [EL 4-review],2 [EL 4-review],27 [EL 3]). Of note, thyroid carcinomas rarely cause airway obstruction, vocal cord paralysis, or esophageal symptoms at their clinical presentation and are more frequently devoid of local symptoms (1 [EL 4-review],28 [EL 4]).

Small differentiated thyroid cancers are frequently devoid of alarming characteristics on physical evaluation (28 [EL 4],29 [EL 3]). However, a firm or hard, solitary, or dominant thyroid nodule that clearly differs from the rest of the gland suggests an increased risk of malignancy (30 [EL 3]). Therefore, despite the low predictive value of palpation, careful inspection and palpation of the thyroid gland and the anterior and lateral nodal compartments of the neck are always strongly recommended (see Table 3).

Suppressed or low levels of thyrotropin (formerly thyroid-stimulating hormone [TSH]) are associated with a decreased probability of malignancy (31 [EL 3]), whereas increased levels of serum TSH, even when the levels are still within reference limits, are statistically associated with an increased risk of cancer in thyroid nodular disease (32 [EL 3]). The clinical role of these epidemiologic findings is still controversial (33 [EL 2]) and is of little use in individual patient treatment. Autonomously functioning thyroid nodules (AFTNs) in adults usually need no cytologic evaluation unless suspicious clinical findings are present (34

[EL 3]) or the topographical correspondence of the “hot” area is uncertain because the prevalence of malignancy is low in hyperfunctioning nodules (35 [EL 4-review]). Multinodular goiters (MNGs) may harbor both hyperfunctioning and “cold” (potentially malignant) lesions (27 [EL 3]). Nodules appearing in patients with Graves' disease or Hashimoto thyroiditis should be managed similar to nodules in any other patient (36 [EL 3]).

Thyroid lesions discovered on CT or MRI performed for other reasons have an uncertain risk of malignancy and should undergo US evaluation before considering FNA biopsy (37 [EL 3],38 [EL 3]).

Nodules detected by <sup>18</sup>F-FDG PET have a high risk of malignancy when thyroid uptake is focal (39 [EL 3],40 [EL 3],41 [EL 2]). Such lesions should undergo a preliminary thyroid US evaluation because the presence of diffuse thyroid uptake may be linked to inflammatory conditions. After confirmation of a true nodular lesion, FNA should be performed.

Focal lesions detected by technetium sestamibi (<sup>99m</sup>Tc MIBI) scans have a high risk of malignancy (42 [EL 3]) and should be evaluated carefully. When MIBI is positive, the risk of malignancy in nodules is around 27%.

### Recommendations for Clinical Evaluation and Diagnosis

- We recommend that the following data be recorded:
  - Age
  - Personal or family history of thyroid disease or cancer
  - Previous head or neck irradiation
  - Rate of neck mass growth
  - Anterior neck pain
  - Dysphonia, dysphagia, or dyspnea
  - Symptoms of hyper- or hypothyroidism
  - Use of iodine-containing drugs or supplements [BEL 2, GRADE A].

Most nodules are asymptomatic and benign, but the absence of symptoms does not rule out malignancy [BEL 2, GRADE A].

- We recommend a careful, focused examination of the thyroid gland and cervical lymph nodes [BEL 2, GRADE A].
- Record the following data:
  - Thyroid dimensions and consistency
  - Location, consistency, size, and number of nodule(s)
  - Neck tenderness or pain
  - Cervical adenopathy [BEL 2, GRADE A].
- The risk of cancer is not substantially different in patients with a solitary nodule versus patients with an MNG [BEL 2, GRADE B].

### 3. US and Other Diagnostic Imaging Studies

#### 3.1. When to Perform Thyroid US

High-resolution US is the most sensitive test available for detecting thyroid nodules, measuring their dimensions, identifying their content, and evaluating any associated changes in the thyroid gland (43 [EL 4-review],44 [EL 4-review]).

If results of palpation are normal, US should be performed when a thyroid nodule is suspected on clinical grounds or risk factors have been recognized (Table 3). The physical finding of suspicious neck lymphadenopathy warrants US examination of lymph nodes and the thyroid gland because of the risk of a metastatic lesion from an otherwise unrecognized papillary microcarcinoma (45 [EL 4-review]).

In all patients with palpable thyroid nodules or MNGs, US should be performed to achieve the following:

- Aid in the diagnosis of difficult cases (e.g., chronic lymphocytic thyroiditis)
- Look for coincidental thyroid nodules or diffuse thyroid gland changes.
- Detect US features suggestive of malignancy and select the lesions for biopsy.
- Assess the presence of extracapsular growth or suspicious lymph nodes.
- Choose biopsy needle gauge and length and the safest approach for the procedure.
- Obtain an objective measure of the baseline volume of the thyroid gland and of lesions assigned to follow-up or nonsurgical therapy.

#### 3.2. How to Describe US Findings

Standardized US reporting criteria should be followed, indicating position, shape, size, margins, content, and echogenic and vascular patterns of the nodule. Potentially malignant nodules or regional lymph nodes should be described carefully (43 [EL 4-review],44 [EL 4-review]).

A conclusive classification of the expected risk of malignancy should be calculated.

#### 3.3. US Criteria for Risk of Malignancy in Palpable Nodules

The risk of cancer is similar in patients with solitary thyroid nodules and multinodular glands (24 [EL 3],29 [EL 3]). For MNGs, cytologic sampling should be focused on lesions with suspicious US features rather than on larger or clinically dominant nodules (46 [EL 3],47 [EL 4-review],48 [EL 2],49 [EL 3],50 [EL 2],51 [EL 3]).

B-mode US and color Doppler characteristics are reported to have varying abilities to predict the risk of malignancy (Table 4). A recent meta-analysis included 41 studies, for a total of 29,678 thyroid nodules (22 [EL 2]). Diagnosis of malignancy was confirmed histologically, while the diagnosis of a benign nodule was confirmed by either histologic evaluation or clinical observation. A higher risk of malignancy, expressed as odds ratio (OR), was associated with the following features: nodule height greater than width (OR, 10.15), absent halo sign (OR,



7.14), microcalcifications (OR, 6.76), irregular margins (OR, 6.12), hypoechogenicity (OR, 5.07), solid nodule structure (OR, 4.69), and intranodular vascularization (OR, 3.76). Chaotic intranodular vascular images, mild hypoechogenicity, and rounded appearance also have a predictive value, albeit a low one (43 [EL 4-review],44 [EL 4-review],45 [EL 4-review]). A further study assessed the risk of malignancy in 2,000 thyroid nodules (63.4% benign and 36.6% malignant) (52 [EL 2]). The distribution of ORs for malignancy was similar, even if not identical: deeply hypoechoic (OR, 6.8; a relevant finding not specifically considered in the 2014 meta-analysis), spiculated or microlobulated margins (OR, 5.9), microcalcifications (OR, 3.3), solid nodule (OR, 2.6), slightly hypoechoic (OR, 2.6), nonparallel (taller than wide) growth (OR, 2.3), and irregular shape (OR, 1.3).

The diagnostic accuracy of these characteristics for cancer is partially blunted by their low sensitivities. Thus, in most thyroid nodules, US signs are not clearly predictive of a malignant lesion, whereas the absence of clearly suspicious features cannot be taken as fully diagnostic for a benign nodule (29 [EL 3]). Notably, the coexistence of 2 or more suspicious US criteria greatly increases the risk of thyroid cancer (29 [EL 3],48 [EL 2], 49 [EL 3],50 [EL 2]).

In the next paragraphs, each of these US signs is separately reviewed and discussed.

### 3.3.1. Size and number

Currently, about 50% of cytologic diagnoses of thyroid malignancy relate to PTMCs  $\leq 10$  mm in diameter (12

[EL 4],14 [EL 3]). Even when the size of a nodule does not predict its benign or malignant nature, consideration should be given that the risk of cancer is slightly higher in nodules  $>4$  cm (21 [EL 2],53 [EL 3]). Moreover, a large size ( $>4$  cm) is a risk factor for a more advanced disease in patients with differentiated thyroid carcinoma (54 [EL 3],55 [EL 3]).

Long-term surveillance of nodular thyroid disease is primarily based on US evaluation of nodule features and size. During follow-up, the appearance of suspicious changes at US examination should prompt repeat FNA of the nodule. Yet, growth is not synonymous with malignancy because benign hyperplastic nodules may have a slow constant growth (56 [EL 1],57 [EL 2],58 [EL 3]), whereas PTMC may be stable for years (15 [EL 3],59 [EL 2]). Rapid growth is observed only in rare aggressive tumors (e.g., anaplastic carcinoma, thyroid lymphoma) and is usually associated with major US and clinical signs of aggressiveness (1 [EL 4-review],2 [EL 4-review],19 [EL 4]). Thus, rather than a sign of malignancy, steady nodule growth is a relevant issue when deciding an appropriate shift to active clinical management (60 [EL 4],61 [EL 4]).

US monitoring is critical for assessing the response to nonsurgical therapies (56 [EL 1],62 [EL 4]). Measurement of the major nodule diameter in its longitudinal axis cannot be considered a reliable index because of the interobserver variability in the measurement of any thyroid nodule diameter, quantified in about 20% (63 [EL 2]). Calculation

**Table 4**  
**US Features of Benign or Malignant Thyroid Nodules**

<b>Table 4</b>	
<b>US Features of Benign or Malignant Thyroid Nodules</b>	
<b>US features indicative of a benign nodule</b>	
Isoechoic spongiform appearance (microcystic spaces comprising $>50\%$ of the nodule)	
Simple cyst with thin regular margins	
Mostly cystic ( $>50\%$ ) nodules containing colloid (hyperechoic spots with comet-tail sign)	
Regular “eggshell” calcification around the periphery of a nodule	
<b>US features indicative of a malignant nodule</b>	
Papillary carcinoma	
Solid hypoechoic (relative to prethyroid muscles) nodule, which may contain hyperechoic foci without posterior shadowing (i.e., microcalcifications)	
Solid hypoechoic nodule, with intranodular vascularity and absence of peripheral halo	
“Taller-than-wide” nodule (AP $>$ TR diameter when imaged in the transverse plane)	
Hypoechoic nodule with spiculated or lobulated margin	
Hypoechoic mass with a broken calcified rim and tissue extension beyond the calcified margin	
Follicular neoplasm (either follicular adenoma or carcinoma)	
Isoechoic or mildly hypoechoic homogeneous nodule with intranodular vascularization and well-defined halo	
<b>Indeterminate US features</b>	
Isoechoic or hyperechoic nodule with hypoechoic halo	
Mild hypoechoic (relative to surrounding parenchyma) nodule with smooth margin	
Peripheral vascularization	
Intranodular macrocalcification	
Abbreviations: AP = anteroposterior; TR = transverse; US = ultrasound.	

of nodule volume with the ellipsoid formula (*longitudinal diameter x transverse (or left to right) diameter x anteroposterior diameter x  $\pi/6$* ) is a more accurate index of changes in nodule size and should be used for follow-up and monitoring the response to medical or ablative treatments (62 [EL 4]). Because volume determination is also influenced by a high (up to 48.9%) interobserver variability (63 [EL 2], 64 [EL 4-review]), a 50% increase in thyroid volume is recommended as the minimum threshold for detection of nodule growth (62 [EL 4]). Assessment of thyroid volume using 3-dimensional US imaging offers greater accuracy and reproducibility than conventional volumetry and should be the preferred modality for volume measurement in nodules with regular shape (65 [EL 3], 66 [EL 3]).

The number of thyroid nodules has a low impact on the risk of malignancy (22 [EL 2], 46 [EL 3]). This parameter should be included in the US report only when the different nodules can be clearly assessed and reliably monitored (46 [EL 3]). In MNGs with diffuse coalescent nodules, and in diffuse colloid cystic hyperplasia with multiple anechoic or mixed lesions, the actual number of nodules may be assessed with difficulty and is of limited clinical usefulness. Therefore, these data can be omitted from the US report.

### 3.3.2. Structure, echogenicity, and texture

The structure of most thyroid nodules is perceived as inhomogeneous because they show a mixed fluid and solid pattern or they show a solid, yet nonuniform, structure due to necrotic or inflammatory changes (43 [EL 4-review], 44 [EL 4-review]). A homogeneous US texture may be observed in completely anechoic cysts and in a few solid “isoechoic” nodules (i.e., nodules exhibiting a US pattern resembling that of the perinodular normal thyroid parenchyma). In chronic autoimmune thyroiditis, homogeneous hyperechoic solid areas—more echoic than the rest of the gland—are common and usually represent zones of normal thyroid parenchyma that are spared from chronic inflammation (43 [EL 4-review]).

Most thyroid carcinomas present as hypoechoic solid lesions, but notably, about half of benign thyroid nodules share the same US appearance. Hence, hypoechogenicity in a solid thyroid nodule is a sensitive (80-85%), yet poorly specific (15-25%), predictor of malignancy (46 [EL 3], 47 [EL 4-review], 48 [EL 2], 49 [EL 3], 50 [EL 2]). Marked hypoechogenicity—defined as a US texture that appears darker than the prethyroid muscles—provides a relevant risk of malignancy with a reported positive predictive value (PPV) up to 94% (62 [EL 4], 67 [EL 2]). The interobserver variability represents a relevant limit of echogenicity assessment (68 [EL 2]). In particular, the coexistence of diffuse thyroiditis in the extranodular tissue may pose major problems for the correct assessment of nodule echogenicity (69 [EL 2]).

Nodules with a predominantly cystic component rarely represent a thyroid carcinoma; yet, thyroid malignancy cannot be completely ruled out. In a series of 392 mixed echoic nodules out of 1,056 consecutive cases undergoing FNA, a 5.4% prevalence of thyroid malignancy was demonstrated in partially cystic nodules (70 [EL 3]). Similarly, 4% and 6% prevalence rates of cystic tumors, respectively, were documented in 2 series of thyroid lesions, each consisting of 55 PTCs (71 [EL 2]). MTC may also present with fluid components (72 [EL 3], 73 [EL 3]). As the risk of malignancy increases with the amount of the solid component, partially cystic thyroid nodules with a  $\geq 50\%$  solid component that is located eccentrically and is intensely vascularized should be carefully evaluated (70 [EL 3], 71 [EL 2]). Coexistent US suspicious features such as microcalcifications or irregular margins or shape suggest an increased risk of malignancy.

A third group of sonographically mixed thyroid lesions is of clinical interest because they are nearly always benign: the “spongiform nodule” group. This lesion, characterized by the aggregation of multiple microcystic components that comprise more than 50% of the volume, is associated with an almost 100.0% benign rate (70 [EL 3]).

### 3.3.3. Margins and shape

Irrespective of their solid or cystic content, most benign nodules show a regular round to oval profile (46 [EL 3], 47 [EL 4-review], 48 [EL 2], 49 [EL 3], 50 [EL 2]). Hence, any deviation from this US appearance deserves attention. Nodule shape and margins should be assessed as independent features, since an oval nodule may present irregular or undefined margins and an irregularly shaped nodule may have well-defined margins. Notably, in large nodules (diameter  $>4$  cm), accurate assessment of the profile and regularity of margins may be difficult.

The presence of ill-defined margins is suspicious for malignancy (29 [EL 3], 46 [EL 3], 47 [EL 4-review], 48 [EL 2], 49 [EL 3], 50 [EL 2]), but because this term is used to cover various US patterns, its interobserver reproducibility is low (68 [EL 3]). Two questions should be addressed: (1) is the nodule clearly demarcated by the extranodular thyroid tissue and (2) is its border regular? Nodule margins are ill-defined when they lack clear demarcation from the surrounding perinodular tissue for most ( $>50\%$ ) of their perimeter. Independent of their definition, margins may present a regular and smooth profile or, alternatively, irregular, spiculated, or lobulated contours. Of note, ill-defined but round margins are often observed in benign nodules and should not be viewed as suspicious (74 [EL 4]). At variance, spiculated margins—even when well-demarcated from surrounding thyroid parenchyma—are a highly specific sign of malignancy (29 [EL 3], 49 [EL 3]).

A regular hypoechoic halo is a typical finding in benign hyperplastic nodules presenting with a regular smooth

profile. In most instances, the peripheral halo corresponds to a pericapsular arrangement of nodule vascularity, as demonstrated by Doppler or power flow mapping (43 [EL 4-review]). Conversely, an unevenly thick or incomplete hypoechoic halo due to fibrotic pseudocapsular structures and inflammatory or necrotic changes is observed in 10 to 12% of PTCs and is frequently associated with an irregular shape (75 [EL 3],76 [EL 3]). Thus, a regular peripheral halo in regularly shaped nodules is suggestive of benignity, but a thick irregular hypoechoic halo in a suspicious-looking nodule increases the probability of malignancy (71 [EL 2]).

A more tall-than-wide shape is highly suggestive of malignancy and may be assessed as the ratio between the anteroposterior and transverse diameters of a nodule. A ratio  $\geq 1$  indicates a taller-than-wide shape and reflects a centrifugal pattern of growth (67 [EL 2]). This definition includes nodules with an anteroposterior diameter longer than the transverse diameter when measured in a longitudinal plane (77 [EL 4]). This sign is specific for malignancy (about 90% in most series) but is far less sensitive, with a false-negative rate up to 40%. In nodules with an irregular shape, the anteroposterior to transverse diameter ratio is less reliable (77 [EL 4]).

We suggest this simple categorization of the nodule shape: (1) oval to round, (2) taller than wide, or (3) irregular (77 [EL 4]).

#### 3.3.4. Calcifications

Thyroid calcifications present a range of different patterns, and the simple indication of “calcifications” in the US report may be misleading. Three major patterns can be described on the basis of size and location: microcalcifications, macrocalcifications (or coarse), and peripheral (or “rim”) calcifications (78 [EL 3],79 [EL 3],80 [EL 2]).

Microcalcifications appearing as tiny (<1 mm) hyperechoic, punctuate spots are usually devoid of posterior shadowing (if not densely crowded) (81 [EL 4]). This finding should be carefully differentiated from the more frequent, and innocuous “comet tail” sign, characterized by bright hyperechoic spots (82 [EL 3]). These spots are usually due either to solid drops of colloid or interfaces in a mixed lesion and are generally predictive of a benign nodule. Conversely, microcalcifications usually correspond to psammoma bodies and are suggestive of PTC (83 [EL 2]). The specificity for malignancy of true microcalcifications is elevated (85-95%), but their sensitivity is low, particularly in small (<1 cm in diameter) nodules (80 [EL 2]).

In the presence of tiny intranodular hyperechoic spots that are not with certainty due to microcalcifications, a frequent confounding factor, it is recommended that they be included in the US report as “hyperechoic spots of uncertain significance.”

Macrocalcifications are frequently due to regressive or necrotic changes and are encountered in large, benign nodular goiters. However, when found in solitary solid nodules, they may be considered as a potential sign of

malignancy (83 [EL 2],84 [EL 3]). In nodules previously treated by ethanol sclerotherapy (PEI) or thermoablation, coarse intranodular calcifications are frequently observed at follow-up and do not represent a suspicious finding (85 [EL 2]).

Peripheral rim calcifications may be present in long-standing hyperplastic nodules. However, the focal discontinuity of the eggshell structure associated with the presence of an outer thick and markedly hypoechoic halo may be predictive of malignancy (86 [EL 2],87 [EL 2]).

#### 3.3.5. Vascularity

Color and power Doppler examinations provide careful visualization of the vascular architecture of thyroid nodules (43 [EL 4-review],44 [EL 4-review]). Basically, 3 major types of color-flow mapping may be identified (75 [EL 3],88 [EL 2]):

- **Peripheral pattern.** Vascularization is visualized along the border of the nodule. Scanty intranodular vascular signals may be detected, but the prevalent blood distribution is perinodular.
- **Intranodular pattern.** Marked vascularity is visible in the central part of the nodule and is clearly enhanced compared with perinodular tissue.
- **Absence of blood flow.** No relevant color-flow mapping is visible in either the peripheral or central part of the nodule.

The value of nodule vascularization in the assessment of the risk of thyroid carcinoma is limited because of the absence of clear-cut differences between benign and malignant lesions. Most malignant nodules (particularly follicular thyroid carcinomas) show a rich intranodular pattern, but this finding may also be present in benign nodules (88 [EL 2],89 [EL 2]). In the latter, the prevalent flow is usually peripheral; however, about 20% of thyroid cancers may show a predominantly peripheral vascular ring (71 [EL 2]). Although a scanty vascularity is normally predictive of benignity, PTMC may appear as completely avascular lesions (77 [EL 4]). Thus, the use of color and power Doppler in thyroid nodule examination only provides complementary information (89 [EL 2]). This parameter is even less reliable in small (<5 mm in diameter) nodules because of the probability of misinterpreting a perinodular vessel as an intranodular vascular signal.

#### 3.3.6. US features in the different types of thyroid neoplasm

Traditional US features of malignancy were derived from series in which PTC was the most frequent thyroid tumor (29 [EL 3]). These sonographic findings are not completely shared by less common thyroid neoplasms, such as follicular and Hürthle cell tumors and medullary thyroid cancer.

- **Histologic variants of PTC.** PTC includes histologic variants that may present US features different from the classic histotype (90 [EL 4]).

The follicular variant of PTC may exhibit a non-suspicious US appearance, with an oval shape, well-defined and regular margins, and an absence of microcalcifications. In addition, the follicular variant of PTC is usually larger than the classic PTC (91 [EL 2],92 [EL 2]).

The tall-cell variant of PTC usually shows the traditional US signs of malignancy. These tumors frequently appear as deeply hypoechoic nodules with lobulated margins and microcalcifications. Extrathyroidal extension and lymph node metastases may also be evident at US examination (93 [EL 2]).

The diffuse sclerosing variant of PTC poses a diagnostic challenge at US examination because the gland may appear enlarged and diffusely hypoechoic, as in Hashimoto thyroiditis. Multiple fine and scattered hyperechoic microcalcifications may confer a “starry night” appearance to wide portions of the thyroid (94 [EL 3],95 [EL 3],96 [EL 3]).

- **Follicular and Hürthle cell tumors.** US appearance of follicular thyroid cancers (FTCs) is frequently different from PTCs because the classic signs of malignancy may be absent (97 [EL 2]). Hypoechoic appearance is seen only in a minority (30-35%) of FTCs, whereas a hypoechoic halo is reported in up to 87% of FTCs (98 [EL 2],99 [EL 2]). Microcalcifications are rare in FTC; whereas macrocalcifications may be observed in 15 to 20% of cases (100 [EL 2]). Most FTCs are solid tumors, but a partially cystic component is more frequent (up to 18%) than in PTC (about 4-6%). These characteristics are shared by both benign and malignant follicular lesions, but the presence of hypoechoic appearance, the irregular thickness of the peripheral halo, and the large size are suggestive of an FTC (101 [EL 2],102 [EL 2]).

Hürthle cell neoplasms present with a heterogeneous US appearance (103 [EL 3]). The echogenicity is usually reduced but hyperechoic tumors are not rare. Vascular organization may range from intense and diffuse to scanty. Similar to FTCs, a large size, irregular margins with an irregularly thickened halo, and an inhomogeneous solid texture are common findings (103 [EL 3],104 [EL 2]).

- **MTC.** Few studies have addressed the issue of US findings in MTC. In a retrospective analysis of 21 MTCs compared with 114 PTCs, solid content, oval-to-round shape, marked hypoechoic appearance, and coarse calcifications were common features (73 [EL 3]). An oval-to-round shape was reported as more frequent in MTCs (57.1%) than in PTCs (22.4%), which more frequently (48%) present with a taller-than-wide shape and a smaller size at diagnosis. The majority (81%) of MTCs were classified as suspicious at US examination, but a larger percentage of MTCs were categorized as US indeterminate in the MTC group (19%) than the PTC

series (6%). Accordingly, in a comparative study of 46 MTCs and 55 PTCs (72 [EL 3]), MTCs were usually larger than PTCs (mean [SD], 23 [15] vs. 11 [11] mm) and sometimes showed a cystic component. Micro- and/or macrocalcifications were a frequent feature of malignancy in a series of 36 MTCs, as they were reported in 61% of patients (105 [EL 3]).

Thus, the US appearance of MTC is variable and may be elusive. In most MTCs, US findings coincide with the signs of malignancy observed in PTCs, but a fraction of them show an indeterminate or, rarely, a benign appearance (106 [EL 4]).

### 3.3.6. US elastography

Clinically, a firm or hard thyroid nodule is associated with an increased risk of malignancy (1 [EL 4-review],2 [EL 4-review]). Elastography evaluates tissue stiffness in palpable and nonpalpable thyroid nodules with real-time US evaluation of an area of interest during the application of an external force, usually delivered by the US probe. Dedicated software can assess the grade of tissue displacement, and this parameter is displayed on a color scale with respect to nodular and extranodular hardness (107 [EL 3]). This technique has shown high sensitivity for thyroid carcinoma with a high (up to 97%) negative predictive value (NPV) in several series (108 [EL 3]). In a multicenter prospective trial, the presence of hardness in at least 50% of the nodule area had a sensitivity for malignancy that was similar to conventional US and color Doppler findings (109 [EL 2]). The presence of at least 1 of 5 US risk factors (i.e., hypoechoic appearance, microcalcifications, irregular margins, intranodular vascularization, and taller-than-wide shape) had 85% sensitivity and 91% NPV. When elastography was combined with US, however, the presence of 1 of the 6 parameters had 97% sensitivity and 97% NPV, reaching an OR of 15.8 (109 [EL 2]). In a meta-analysis of 12 studies assessing 1,180 thyroid nodules (817 benign and 363 malignant), the frequently used threshold for a high risk of malignancy (elasticity scores between 2 and 3) had a sensitivity of 86.0% and a specificity of 66.7%, with positive and negative likelihood ratios and a diagnostic OR of 3.82, 0.16, and 27.51, respectively (110 [EL 2]). Thus, the selection of nodules that do not need cytologic evaluation appears more reliable by combining elastography with B-mode US and color Doppler evaluation (111 [EL 2]).

A few pitfalls limit the diagnostic utility of real-time elastography, which is still strongly operator dependent and lacks a standardized method for data reporting (108 [EL 3]). Moreover, cystic lesions and nodules with calcified shells are not suitable for elastographic evaluation. Because the index nodule must be clearly distinguishable from the surrounding tissue, lesions in areas difficult to scan, MNGs with coalescent nodules, microcarcinomas, and nodules in chronic thyroiditis are less suitable for this

assessment (108 [EL 3]). Technical advancements and uniform reporting terminology are needed to better define the overall diagnostic accuracy, indications, and cost-effectiveness of this technique.

Recently, quantitative elastographic techniques have been developed, such as the determination of strain index, the acoustic radiation force impulse (112 [EL 2]), and the supersonic shear wave (113 [EL 2],114 [EL 3]). A study of 173 thyroid nodules with histologic verification (77 benign and 96 malignant) assessed the diagnostic performance of conventional US and acoustic radiation force impulse in PTMCs. Hypoechoogenicity, taller-than-wide shape, elastography score of 4 or higher, and shear wave  $>3.10$  m/s were independent risk factors for predicting PTMC. Acoustic radiation force impulse appears to reflect the overall elastic properties and may provide quantitative elasticity information in small-size PTMCs (112 [EL 2]). The sensitivity of traditional US findings, used in risk stratification of thyroid lesions, was improved by adding elastographic evaluation.

Of note, in a study of 142 nodules with indeterminate cytologic characteristics, elastography showed 96.8% sensitivity and 91.8% specificity with an increased NPV for malignancy (115 [EL 2]). Hence, data provided by elastography may be considered as an additional diagnostic criterion for refining the management of thyroid lesions that are indeterminate at FNA.

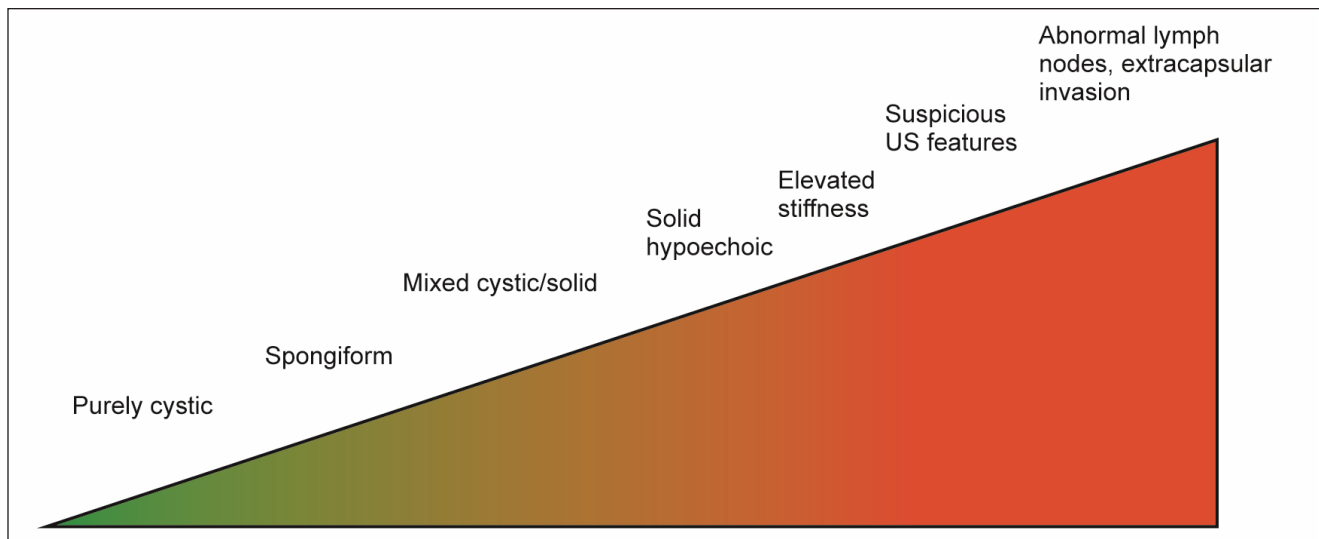
### 3.3.7. US criteria for FNA

Extension of thyroid lesions beyond the capsule, invasion of prethyroid muscles, and infiltration of the trachea or recurrent laryngeal nerves are infrequent, but they are US findings of concern that demand immediate cytologic assessment (43 [EL 4-review],102 [EL 2]).

The presence of enlarged lymph nodes with cystic changes, microcalcifications, or absence of hilum is

highly suspicious (45 [EL 4-review],116 [EL 4],117 [EL 2]). Rounded appearance and chaotic hypervascularity are common but less specific characteristics of malignancy. Suspicious lymph nodes and any coexistent thyroid nodule, whatever the size, always warrant FNA biopsy and Tg or calcitonin determination, according to the clinical suspicion, on FNA lymph node washout (118 [EL 2],119 [EL 2],120 [EL 2]).

Malignancy is not significantly less frequent in smaller ( $\leq 10$  mm) nodules (29 [EL 3]). A meta-analysis showed that the OR for malignancy of nodules  $>4$  cm was 1.63, but lower than the other suspicious thyroid features (22 [EL 22]). Even if a diameter cutoff for cancer risk cannot be established, a balance between the risks of a potentially delayed diagnosis and those of superfluous diagnostic procedures or surgery should be considered. Thus, suspicious nodules  $<10$  mm may be considered for either FNA or watchful waiting on the basis of clinical setting, technical expertise, and patient preference (61 [EL 4]). Due to the nonnegligible prevalence of extracapsular extension in subcentimetric tumors (29 [EL 3]), suspicious (high-risk) lesions  $<10$  mm should receive FNA for early diagnosis and treatment when subcapsular (especially if associated with capsular abutment) (120b [EL 3], 121 [EL 3]), in the presence of suspicious lymph nodes or extrathyroid spread, or in the case of personal or family history of thyroid carcinoma or of coexistent suspicious clinical findings (e.g., dysphonia). The risk of extrathyroidal spread or lymph node involvement decreases with the reduction in tumor size, and an aggressive disease course is rare in incidentally discovered microcarcinomas  $<5$  mm (15 [EL 3],121 [EL 3],122 [EL 4-review]). Because of the increased risk of inadequate or inappropriate sampling (121 [EL 3]), incidental thyroid lesions with a diameter  $<5$  mm should not be biopsied (123 [EL 3]).



**Fig. 1.** Indications for FNA biopsy according to US findings. Suspicious US findings are markedly hypoechoic nodule, intranodular microcalcifications, more-tall-than-wide shape, and spiculated or lobulated margins. FNA = fine-needle aspiration; US = ultrasonography.

### 3.4. US Classification Systems

Information provided by the evaluation of US signs needs to be translated into stratification of malignancy risk, to discriminate the nodules to be submitted for FNA from those that can be referred to US surveillance (124 [EL 4-review]) (Fig. 1). A comparative study of the predictive value for malignancy of 3 major classification systems (125 [EL 2]) showed that criteria proposed by Kim et al (50 [EL 2]) had higher sensitivity, whereas the AACE/AME/ETA classification (60 [EL4]) had higher specificity. However, the sensitivity, specificity, and diagnostic accuracy of US signs associated with thyroid malignancy are variable in different series and appear operator-dependent (124 [EL 4-review]). The combination of 2 or more suspicious features increases the specificity for malignancy but, unfortunately, is associated with a low US sensitivity for cancer (29 [EL 3]). Moreover, even detailed US descriptions of thyroid nodules may not be clearly focused on the indications for FNA biopsy.

These problems have led to the introduction of a standardized imaging reporting data system for thyroid nodules, based on a stratified risk of malignancy, analogous to the systems developed for breast lesions (126 [EL 4]). Standardized US reporting systems may reduce the inconsistency of US descriptive reports, facilitate cross-talk among clinicians and pathologists, and ease the audit procedures on clinical management of thyroid nodules. In general, the accuracy of these categorizations parallels their complexity. At least 4 classification systems of thyroid US findings have been proposed: Thyroid Imaging Reporting and Data System (TIRADS), which focuses on the NPV of thyroid US (127 [EL 2]); South Korean US-Based Management of Thyroid Nodules; Kim Classification of Thyroid US findings; and British Thyroid Association (BTA) Thyroid Cancer Guidelines (50 [EL 2],61 [EL 4],77 [EL 4],128 [EL 2]).

The assumption of TIRADS is that the risk of malignancy increases in parallel with a greater number of suspicious US features. The TIRADS scheme is based on 10 US patterns combined into categories with increasing risk of malignancy. A validation study showed 88% sensitivity and 49% specificity, with 49% PPV, 88% NPV, and 94% accuracy for diagnosis of malignancy. With the adoption of TIRADS criteria, clearly benign nodules no longer would be sampled, the number of FNAs would be reduced, and an improved benign to malignant FNA ratio would be achieved (127 [EL 2]). Kim et al (128 [EL 2]) studied 1,289 thyroid nodules in 1,036 patients who underwent thyroid US, US-FNA, and thyroid surgery. Each thyroid nodule was prospectively classified into 1 of 5 diagnostic categories following real-time US examination: benign, probably benign, borderline, possibly malignant, and malignant. For solid and partially cystic thyroid nodules, the sensitivity, specificity, PPV, NPV, and accuracy of US diagnosis were 86.1% and 66.7%, 90.0% and 88.9%, 94.3% and 75.0%,

77.3% and 84.2%, and 87.5% and 81.5%, respectively (128 [EL 2]).

In the South Korean classification system (49 [EL 3],77 [EL 4]), nodules were classified according to US findings into 3 categories—probably benign, indeterminate, and suspicious for malignancy. A nodule was defined as *suspicious for malignancy* if at least 1 of the following findings was present: taller-than-wide shape, spiculated margins, marked hypoechogenicity, and micro- or macrocalcifications. *Indeterminate* nodules were characterized by US findings without definite malignant or benign features: isoechogenicity, mild hypoechogenicity, or hyperechogenicity; an ovoid-to-round shape; a smooth or ill-defined margin; and presence of continuous rim calcification. Simple cysts, predominantly (>50%) cystic nodules with reverberating artifacts and isoechoic nodules with a spongiform appearance were defined as *probably benign* nodules (77 [EL 4]).

The BTA system classifies the thyroid US features in 5 categories at increasing risk of malignancy, from U1 (normal thyroid gland) to U5 (very suspicious lesion) (61 [EL 4]). The U2 (benign) category is characterized by isoechoic or mildly hyperechoic nodules with (1) halo, (2) cystic change with or without “ring down sign,” (3) microcystic or spongiform appearance, (4-5) peripheral eggshell calcification, or (6) peripheral vascularity. The U3 (indeterminate/equivocal) category comprises (1) homogeneous, hyperechoic (markedly), solid nodules with halo (follicular lesion); (2) hypoechoic nodules with equivocal echogenic foci cystic change; or (3) mixed/central vascularity. The U4 (suspicious) category is characterized by (1) solid hypoechoic (cf. normal thyroid) or (2) solid very hypoechoic (cf. strap muscle) nodules with (3) disrupted peripheral calcification and (4) hypoechoic lobulated outline. The U5 (malignant) category comprises (1) solid, hypoechoic nodules with lobulated or irregular outline and with or without microcalcification (suggestive of papillary carcinoma) and (2) solid, hypoechoic nodules with lobulated or irregular outline and with or without globular calcification (suggestive of medullary carcinoma). Other U5 malignant features are (3) intranodular vascularity, (4) taller-than-wide shape (anteroposterior>transverse diameter), and (5) characteristic associated lymphadenopathy (61 [EL 4]).

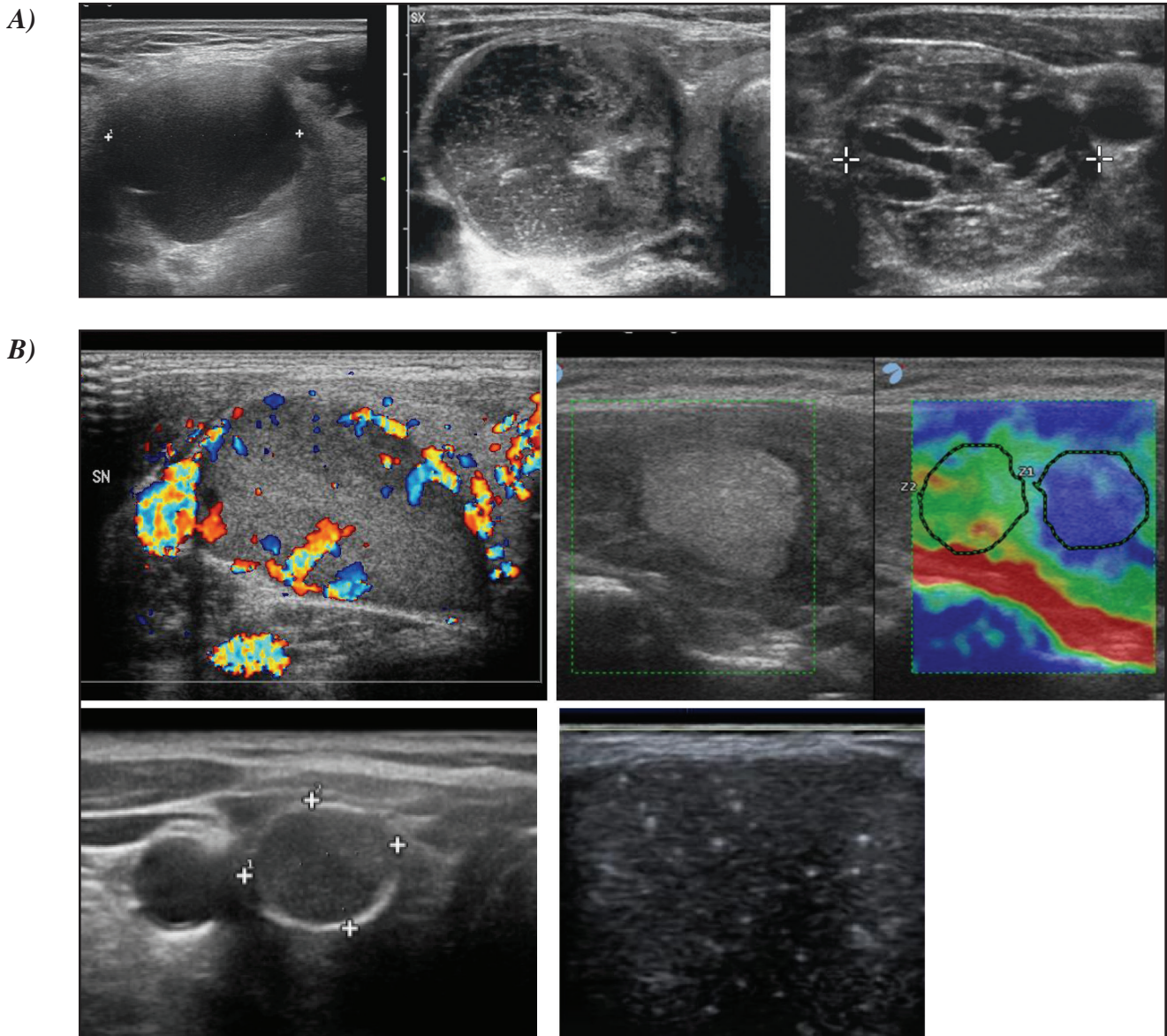
In conclusion, in thyroid US reports, a conclusive evaluation that stratifies thyroid lesions on the basis of their US features permits a rapid and reliable communication of the expected risk of cancer and guides the decision for FNA (129 [EL 2],130 [EL 2]). The TIRADS system demonstrates a good correlation with cytologic findings (131 [EL 3]) and, because of its complexity, is best suited for thyroid referral centers, where it represents an effective tool for the analysis and comparison of data in clinical studies. The main US Classification Systems for the risk of malignancy are summarized in Table 5. For clinical

**Table 5**  
**Comparison of the 2016 AACE/ACE-AME, 2015 ATA, and 2014 BTA Thyroid Nodule Ultrasound Classification Systems<sup>a</sup>**

AACE/ACE-AME	ATA	BTA
<p><b>1 Low-risk lesion</b></p> <ul style="list-style-type: none"> <li>• Cysts (fluid component &gt;80%)</li> <li>• Mostly cystic nodules with reverberating artifacts and not associated with suspicious US signs</li> <li>• Isoechoic spongiform nodules, either confluent or with regular halo</li> </ul>	<p><b>Benign</b> Purely cystic nodules (no solid component)</p> <p><b>Very low suspicion</b> Spongiform or partially cystic nodules without any of the US features described in low-, intermediate- or high-suspicion patterns</p> <p><b>Low suspicion</b> Isoechoic or hyperechoic solid nodule, or partially cystic nodule with eccentric solid area <u>without</u>:</p> <ul style="list-style-type: none"> <li>• Microcalcifications</li> <li>• Irregular margin</li> <li>• Extrathyroidal extension</li> <li>• Taller than wide shape</li> </ul>	<p><b>U1 Normal</b></p> <p><b>U2 Benign</b></p> <ul style="list-style-type: none"> <li>A. Halo, isoechoic, mildly hyperechoic</li> <li>B. Cystic change ± ring-down sign (colloid)</li> <li>C. Microcystic/spongiform</li> <li>D-E. Peripheral eggshell calcification</li> <li>F. Peripheral vascularity</li> </ul>
<p><b>2 Intermediate-risk thyroid lesion</b> Slightly hypoechoic (vs. thyroid tissue) or isoechoic nodules, with ovoid-to-round shape, smooth or ill-defined margins May be present:</p> <ul style="list-style-type: none"> <li>• Intranodular vascularization</li> <li>• Elevated stiffness at elastography,</li> <li>• Macro or continuous rim calcifications</li> <li>• Indeterminate hyperechoic spots</li> </ul>	<p><b>Intermediate suspicion</b> Hypoechoic solid nodule with smooth margins <u>without</u>:</p> <ul style="list-style-type: none"> <li>• Microcalcifications</li> <li>• Extrathyroidal extension</li> <li>• Or taller than wide shape</li> </ul>	<p><b>U3 Indeterminate/equivocal</b></p> <ul style="list-style-type: none"> <li>A. Homogeneous, markedly hyperechoic, solid, halo (follicular lesion)</li> <li>B. Hypoechoic (?), equivocal echogenic foci, cystic change (irregular)</li> <li>C. Mixed/central vascularity</li> </ul>
<p><b>3 High-risk thyroid lesion (50-90%)</b> Nodules <u>with at least 1</u> of the following features:</p> <ul style="list-style-type: none"> <li>• Marked hypoechogenicity (vs. prethyroid muscles)</li> <li>• Spiculated or lobulated margins</li> <li>• Microcalcifications</li> <li>• Taller-than-wide shape (AP&gt;TR)</li> <li>• Extrathyroidal growth</li> <li>• Pathologic adenopathy</li> </ul> <p>Expected risk of malignancy in accordance with the presence of 1 or more suspicious findings.</p>	<p><b>High suspicion</b> Solid hypoechoic nodule or solid hypoechoic component of partially cystic nodule <u>with 1 or more</u> of the following features:</p> <ul style="list-style-type: none"> <li>• Irregular margins (infiltrative, microlobulated)</li> <li>• Microcalcifications</li> <li>• Taller than wide shape</li> <li>• Rim calcifications with small extrusive soft tissue component</li> <li>• Evidence of extrathyroidal extension</li> </ul>	<p><b>U4 suspicious</b></p> <ul style="list-style-type: none"> <li>A. Solid, hypoechoic (cf. thyroid)</li> <li>B. Solid, very hypoechoic (cf. strap muscle)</li> <li>C. Disrupted peripheral calcification, hypoechoic</li> <li>D. Lobulated outline</li> </ul> <p><b>U5 Malignant</b></p> <ul style="list-style-type: none"> <li>A. Solid, hypoechoic, lobulated/irregular outline, microcalcification (papillary carcinoma?)</li> <li>B. Solid, hypoechoic, lobulated/irregular outline, globular calcification (medullary carcinoma?)</li> <li>C. Intranodular vascularity</li> <li>D. Shape tall&gt;wide (AP&gt;TR)</li> <li>E. Characteristic associated lymphadenopathy</li> </ul>

Abbreviations: AACE/ACE/AME = American Association of Clinical Endocrinologists/American College of Endocrinology/ Associazione Medici Endocrinologi; AP = anteroposterior; ATA = American Thyroid Association; BTA = British Thyroid Association; TR = transverse; US = ultrasonography.

<sup>a</sup> Adapted from: 2015 ATA Management Guidelines for Adult Patients with Thyroid Nodules and Differentiated Thyroid Carcinoma. *Thyroid.* 2016;26:1-133; British Thyroid Association Guidelines for the Management of Thyroid Carcinoma. *Clin Endocrinol.* 2014;81 Suppl 1:1-122; 2016 AACE/ACE-AME Clinical Practice Guidelines for the Diagnosis and Management of Thyroid Nodules. *Endocr Pract.* 2016;22 Suppl 1:1-59.



**Fig. 2.** Thyroid ultrasound features and risk of malignancy.

**A) Low-Risk Ultrasound Features**

- Thyroid Cyst
- Mostly cystic nodule with reverberating artifacts
- Isoechoic spongiform nodule

**B) Intermediate-Risk Ultrasound Features**

- Isoechoic nodule with central vascularity
- Isoechoic nodule with macrocalcifications
- Isoechoic nodule with indeterminate hyperechoic spots
- Isoechoic nodule with elevated stiffness on elastography



C)

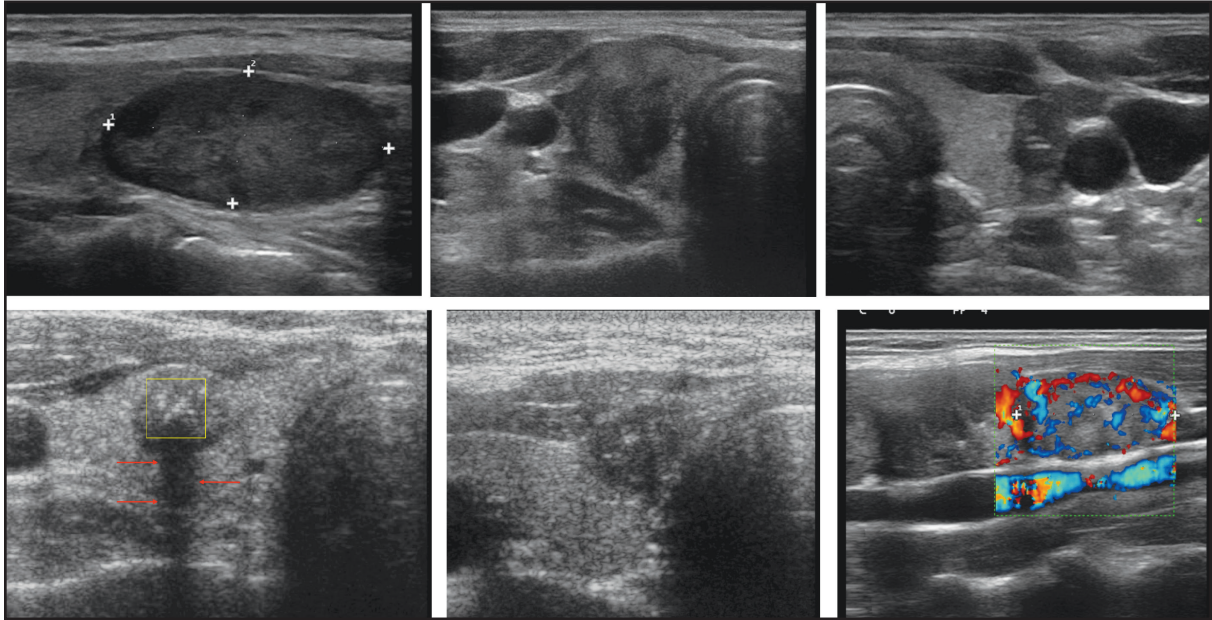


Fig. 2. (Continued)

C) **High-Risk Ultrasound Features**

- Marked hypoechogenicity
- Microcalcifications
- Irregular (speculated) margins
- More tall than wide
- Extracapsular growth
- Suspicious regional lymph node

practice, we suggest the use of a simplified 3-class US rating system for risk of thyroid carcinoma that is associated with a progressive risk of malignancy (Fig. 2).

## 3.5. Indications for US-Guided Fine-Needle Aspiration

**Class 1. Low-risk thyroid lesion.**

- Mostly cystic (>50%) nodules with reverberating artifacts.
- Spongiform nodules not associated with any suspicious US or elastographic findings (expected risk of malignancy, about 1%).

**Class 2. Intermediate-risk thyroid lesion.**

- Slightly hypoechoic or isoechoic nodules with ovoid-to-round shape and smooth or ill-defined margins.
- Either intranodular vascularization, macro- or continuous rim calcifications, increased stiffness at elastography, or hyperechoic spots of uncertain significance may be present (expected risk of malignancy, 5-15%).

**Class 3. High-risk thyroid lesion.**

- Nodules with at least 1 of the following findings: marked hypoechogenicity, spiculated or microlobulated margins, microcalcifications, taller-than-wide shape, or presence of extrathyroidal growth or pathologic lymphadenopathy (expected risk of

malignancy, 50-90%, according to the presence of 1 or more suspicious findings).

As a general rule, which may be modified on the basis of the clinical setting and operator expertise, we recommend the following:

- In light of the low clinical risk, nodules <5 mm should be monitored, rather than biopsied, irrespective of their sonographic appearance.
- In nodules with a major diameter of 5 to 10 mm that are associated with suspicious US signs (high-US-risk thyroid lesions), consider either FNA sampling or watchful waiting on the basis of the clinical setting and patient preference. Specifically, FNA is recommended for the following nodules:
  - Subcapsular or paratracheal lesions
  - Suspicious lymph nodes or extrathyroid spread
  - Positive personal or family history of thyroid cancer
    - History of head and neck irradiation
    - Coexistent suspicious clinical findings (e.g., dysphonia)
- In nodules >10 mm that are associated with suspicious US signs (high US risk thyroid lesions), FNA is always recommended.

- In nodules >20 mm that are isoechoic, slightly hypoechoic, or hyperechoic with ovoid-to-round shape and smooth or ill-defined margins (intermediate US risk thyroid lesions), FNA is recommended.
- In spongiform or dominantly cystic nodules without suspicious US findings (low US risk thyroid lesions), FNA is recommended **only** when nodules are >20 mm and increasing in size or associated with a high-risk history and before thyroid surgery or minimally invasive ablation therapy.

### 3.6. Other Diagnostic Imaging Techniques

MRI and CT should not be routinely used in nodular thyroid disease because they are rarely diagnostic for malignant lesions except in advanced cases (37 [EL 3]). However, MRI and CT are of value when the following assessments are desired for clinical management: size, substernal extension of a nodular goiter, airway compression, or presence of pathologic lymph nodes in cervical regions that are not visualized by US scan (136 [EL 4-review]). CT contrast medium usually contains iodine, decreases subsequent uptake of radioiodine, and may induce hyperthyroidism, especially in iodine-deficient geographic areas (137 [EL 4]).

<sup>18</sup>FDG PET/CT has been proposed to better define the risk of malignancy in thyroid nodules with indeterminate cytologic characteristics. Several noncontrolled studies and 2 meta-analyses have showed an added (about 90%) NPV for thyroid malignancy of this imaging technique (138 [EL 4], 139 [EL 4]). However, its diagnostic accuracy appears to be close to that obtained by B-mode US examination (140 [EL 2]). Thus, the added cost and limited accessibility of this imaging technique disfavor its routine use.

### 3.7. Other US Techniques

First- and second-generation contrast agents provide only ancillary data for the diagnosis of malignant thyroid nodules. They offer a modest improvement over the information obtainable with traditional color or power Doppler examinations (132 [EL 4]). In a retrospective study, 213 thyroid nodules underwent preoperative contrast medium-enhanced US (CEUS) and were submitted to surgery. Quantitative parameters of the time-intensity curve, such as the maximum intensity of peak (IMAX), a rise time from 10% to 90% of the IMAX, and the time to peak, were compared between benign and malignant nodules. There were no significant differences in the rise time or the time to peak among thyroid papillary carcinoma, nodular goiter, and follicular adenoma whereas a significant difference was reported in the IMAX (133 [EL 2]). In another study of 182 thyroid nodules, ring enhancement and homogeneity of enhancement on CEUS were reported as valuable indicators, with ORs >20 in the differential diagnosis of benign and malignant thyroid nodules (134 [EL 3]).

Currently, use of US contrast agents should be restricted to definition of the size and limits of necrotic zones after US-guided ablation procedures (135 [EL 4-review]).

## Recommendations: Thyroid Ultrasonography and other Diagnostic Imaging Studies

### 3.1. When to Perform Thyroid US

- US evaluation is recommended for patients who are at risk for thyroid malignancy; have palpable thyroid nodules or goiter; or have neck lymphadenopathy suggestive of a malignant lesion [BEL 2, GRADE A].
- US evaluation is not recommended as a screening test for the general population or for patients with a normal thyroid palpation with a low clinical risk of thyroid disease [BEL 4, GRADE C].

### 3.2. How to Describe US Findings

We recommend the following approach to describe US findings:

- Focus the US report on stratification for risk of malignancy.
- Describe position, dimensions, shape, margins, content, echogenic pattern, and vascular features of the nodule(s).
- For multiple nodules, detail the nodule(s) bearing the US characteristics associated with malignancy, rather than describing the largest (dominant) nodule.
- For suspicious regional neck lymph nodes, describe the cervical compartment, number, shape, dimensions, margins, content, echogenic pattern, presence of hilum, and vascular features [BEL 2, GRADE A].

### 3.3. US Rating of the Risk of Malignancy

- In thyroid US reports, add to the description of US features a conclusive evaluation that stratifies thyroid lesions on the basis of their risk of malignancy, to reliably communicate the estimated risk of cancer [BEL 3, GRADE B].

### 3.4. US Classification Systems

The following US rating system of the risk of malignancy is suggested:

- **Class 1. Low-risk thyroid lesion.**
  - Mostly cystic (>50%) nodules with reverberating artifacts that are not associated with suspicious US signs
  - Isoechoic spongiform nodules confluent or with regular halo
  - The expected risk of malignancy is about 1%.
- **Class 2. Intermediate-risk thyroid lesion.**
  - Slightly hypoechoic nodules (cf. surrounding thyroid tissue) and isoechoic nodules

- with ovoid-to-round shape and smooth or ill-defined margins
- Either intranodular vascularization, elevated stiffness at elastography, macro- or continuous rim calcifications, or hypoechoic spots of uncertain significance may be present
- The expected risk of malignancy is 5 to 15%.
- **Class 3. High-risk thyroid lesion.** Nodules with at least one of the following suspicious features:
  - Marked hypoechogenicity (compare prethyroid muscles)
  - Spiculated or microlobulated margins
  - Microcalcifications
  - Taller-than-wide shape
  - Evidence of extrathyroidal growth or pathologic adenopathy
  - The expected risk of malignancy is 50 to 90% in accordance with the presence of one or more suspicious findings [BEL 4, GRADE C].

### 3.5. Indications for FNA

#### 3.5.1. How to select nodule(s) for FNA

- In the selection of nodules for FNA, consider a balance between the risk of a potentially delayed diagnosis and that of unnecessary diagnostic procedures or surgery [BEL 4, GRADE C].
- In light of the low clinical risk, nodules with a major diameter <5 mm should be monitored, rather than biopsied, with US irrespective of their sonographic appearance [BEL 3, GRADE B].
- In nodules with a major diameter 5 to 10 mm that are associated with suspicious US signs (high-US-risk thyroid lesions), consider either FNA sampling or watchful waiting on the basis of the clinical setting and patient preference [BEL 3, GRADE B].
- Specifically, FNA is recommended when the following is present:
  - Subcapsular or paratracheal lesions
  - Suspicious lymph nodes or extrathyroid spread
  - Positive personal or family history of thyroid cancer
  - Coexistent suspicious clinical findings (e.g., dysphonia) [BEL 2, GRADE A]
- FNA is recommended for the following nodules:
  - High US risk thyroid lesions  $\geq 10$  mm
  - Intermediate US risk thyroid lesions >20 mm

- Low US risk thyroid lesions only when >20 mm and increasing in size or associated with a risk history and before thyroid surgery or minimally invasive ablation therapy [BEL 2, GRADE A]

- FNA is not recommended for nodules that are functional on scintigraphy (see difference in recommendations for children, Section 8.4) [BEL 2, GRADE B].

#### 3.5.2. FNA of multinodular glands and lymph nodes

- We do not recommend the biopsy of more than 2 nodules when they are selected on the basis of previously described criteria [BEL 3, GRADE C].
- If a radioisotope scan is available, we recommend not biopsying hot areas [BEL 2, GRADE B].
- In the presence of suspicious cervical lymphadenopathy, perform FNA for cytologic assessment of lymph node(s) as well as the ipsilateral suspicious nodule(s) [BEL 2, GRADE A].
- We favor the determination of Tg or calcitonin, according to clinical indications, on FNA washout of suspicious lymph nodes [BEL 2, GRADE A].

#### 3.5.3. FNA of complex thyroid nodule(s)

- We recommend sampling the solid component of the lesion by FNA biopsy [BEL 3, GRADE B].
- Sample preferentially the vascularized areas of the complex lesion [BEL 4, GRADE C].
- Submit both the FNA specimen and the drained fluid for cytologic examination [BEL 2, GRADE A].

#### 3.5.4. FNA of thyroid incidentalomas

- Manage thyroid incidentalomas according to the previously described criteria for nodule diagnosis [BEL 2, GRADE A].
- Always perform US evaluation of incidentalomas detected by CT or MRI prior to FNA [BEL 2, GRADE A].
- Thyroid incidentalomas detected by PET with  $^{18}\text{F}$ -FDG (focal uptake, in particular) should undergo US evaluation and FNA because of the high risk of malignancy [BEL 2, GRADE A].

### 3.6. Other Diagnostic Imaging Techniques

- MRI and CT are not recommended for routine thyroid nodule evaluation [BEL 2, GRADE A].
- Consider MRI and CT for assessment of size, airway compression, substernal extension of a nodular goiter, or presence of pathologic lymph nodes in cervical regions not visualized by US scan [BEL 3, GRADE B].
- PET/CT may provide additional information about the risk of malignancy in thyroid

nodules with indeterminate cytologic results; however, because of the insufficient diagnostic accuracy, high cost, and limited accessibility, we do not suggest its routine use as a diagnostic tool [BEL 2, GRADE A].

- Consider PET/CT only for the preoperative staging of malignant nodules with aggressive features [BEL 2, GRADE A].

### 3.7. Other US Techniques

- Elastography provides information about nodule stiffness, which is complementary to grayscale findings [BEL 2, GRADE B].
- Elastography should not be used as a substitute for grayscale US examination, but rather as a complementary tool in nodules with indeterminate US or cytologic characteristics [BEL 2, GRADE A].
- In nodules with increased stiffness, we recommend FNA [BEL 2, GRADE B].
- Use of US contrast media for the diagnostic evaluation of thyroid nodules is not recommended [BEL 3, GRADE B].
- Use of US contrast media is recommended only for the assessment of the area of tissue ablation induced by minimally invasive techniques [BEL 3, GRADE B].

## 4. Thyroid Biopsy

### 4.1. Thyroid FNA

Clinical management of thyroid nodules should be guided by the combination of clinical data, US evaluation, and FNA biopsy (1 [EL 4-review]). FNA under US guidance is currently the best triage test for the preoperative evaluation of thyroid nodules (60 [EL 4]) (Table 6).

We recommend performing FNA with 23- to 27-gauge needles, with or without aspiration, depending on nodule structure and vascularization (43 [EL 4-review],50 [EL 2],141 [EL 4]). In rare cases, as in cystic lesions with a dense, sticky colloid content, the use of large-bore needles (18 to 21 gauge) may be necessary. A preliminary injection of a small amount (about 10% of the fluid content of the cyst) of 95% ethanol or isotonic saline is frequently followed by a successful drainage of sticky colloid collections (43 [EL 4-review]).

Since the risk of bleeding does not seem to be significantly affected by antithrombotic agent use, the decision to withdraw these drugs for patients who are undergoing FNA should be based on individual circumstances and consultation with the referring physician (143 [EL 4]). The interruption of antithrombotic therapy decreases the risk of procedure-related bleeding (142 [EL 3]) but should be balanced with the possibility of major cardio- and cerebrovascular events due to the return to pretreatment thromboembolic risk (143 [EL 4]). Even though in a study of 593 patients who underwent FNA, only 2 hematomas were

reported in 144 patients who were taking antithrombotic medications while 4 bleeding episodes were observed in 449 patients who did not take anticoagulant drugs (144 [EL 2]), antithrombotic withdrawal seems to be generally appropriate. If the patient is taking warfarin, the medication may be withdrawn 5 days before the procedure, and FNA can be performed if the international normalized ratio is <1.7 (143 [EL 4]). During this period, enoxaparin should be given subcutaneously twice a day, and the anticoagulant therapy may be restarted the day after FNA. The antiplatelet agents aspirin and clopidogrel should be withdrawn for 3 to 5 days before FNA. In those cases who are maintained under treatment, FNA must always be performed under US guidance by a skilled operator with thin (25- to 27-gauge) needles and a limited number of passes after careful discussion with the patient. The risk of significant FNA-related bleeding is decreased by a few minutes of manual compression immediately after the procedure. In these patients, the neck should be re-examined with US at 15 to 30 minutes after FNA.

Since a common cause of a false-negative cytologic diagnosis is sampling error (50 [EL 2],145 [EL 3]), cytologic diagnosis is more reliable, and the nondiagnostic rate is lower when FNA is performed using US guidance (146 [EL 4],147 [EL 3],148 [EL 4]). Hence, the use of US guidance for FNA is recommended, whenever possible, for all thyroid nodules or cervical lesions.

A requisition form including nodule size and location and all relevant clinical and US information should always accompany the cytologic specimen. Sampling site, number of submitted slides, and/or additional biopsy specimens should also be indicated (149 [EL 4],150 [EL 4],151 [EL 4-consensus],152 [EL 4]).

The rating of the US risk of malignancy, based on a validated US classification system (see Section 3.4), should always be added (61 [EL 4]).

### 4.2. Cytologic Diagnosis

Thyroid smears or liquid-based cytologic specimens should be reviewed by a cytopathologist whose focus is dedicated to thyroid disease (152 [EL 4]). The cytology report should be detailed and clear. An accurate, yet concise, description of the cytologic sample should be followed by a conclusion (150 [EL 4],152 [EL 4]). A number of reporting systems for thyroid cytology, based on various classes, have been proposed by different institutions to standardize the communication between pathologists and clinicians and to provide better support for clinical decisions. Currently, a substantial agreement on thyroid cytology reporting is present, with minor differences, in 3 classification systems (151 [EL 4-consensus],152 [EL 4],153 [EL 3]) (Table 2). Their clinical validity is justified by the reliable correlation between each cytologic class and the histologic outcome in predicting a benign versus a malignant lesion (154 [EL 2]). Cytologic diagnoses should be organized in the 5 major classes of nondiagnostic, benign,

indeterminate, suspicious, and malignant. Indeterminate cytologic characteristics should be subclassified in 2 subclasses based on differences in the expected risk of malignancy (see Table 2) (151 [EL 4-consensus],155 [EL 4]).

**Thyroid 1. Nondiagnostic.** Nondiagnostic specimens may be due to an insufficient number of thyroid cells, associated with cystic fluid or bloody smears, or due to a poor technique in preparing slides, thereby leading to compromised preservation or staining of the material (156 [EL 4],157 [EL 4]). Criteria for adequacy are difficult to standardize, as shown by the variability among institutions in classifying FNA as nondiagnostic (154 [EL 2]). However, a cytologic sample is usually labeled *diagnostic* when it contains a minimum of 6 groups of well-preserved thyroid epithelial cells with at least 10 cells per group (151 [EL 4-consensus],157 [EL 4]). Specimens characterized by a cytologic atypia that raises a strong suspicion of malignancy do not require the minimum amount of follicular cells for adequacy to be classified as *suspicious* (151 [EL 4-consensus],152 [EL 4]).

The rate of nondiagnostic FNAs is influenced by nodule structure, technical factors, and operator and cytopathologist expertise (145 [EL 3],158 [EL 3]). Hence, FNA biopsy is performed more reliably in high-volume centers (81 [EL 4]). A nondiagnostic rate as high as 15% has been reported, but the nondiagnostic rate should not exceed 10% (with the exclusion of cystic lesions) (141 [EL 4],152 [EL 4]).

The risk of malignancy in nondiagnostic specimens is not precisely defined because of the selection bias of surgical series, but it is nonnegligible (156 [EL 4],157 [EL 4]). In a meta-analysis of 3,271 cases, the prevalence of malignancy in some patients (16%) who underwent an operation because of clinical suspicious findings was 16.8% (154 [EL 2]).

Cytologic samples obtained from thyroid lesions that are nearly completely cystic at US examination and are characterized by erythrocytes, cellular debris, and hemosiderin-laden macrophages, with a number of thyrocytes that do not fulfill the requirements for adequacy should be classified as *inadequate but consistent with a cystic lesion* (150 [EL 4],151 [EL 4-consensus],152 [EL 4]). These lesions are at a low risk of malignancy.

**Thyroid 2. Benign.** A benign (or negative for malignancy) diagnosis is the most common cytologic finding, with a range in different series from 54 to 74% of cases (154 [EL 2]). Benign cytologic specimens include samples from colloid nodules, hyperplastic nodules, lymphocytic or granulomatous thyroiditis, benign cysts, and other, infrequent nonmalignant conditions (150 [EL 4],151 [EL 4-consensus],152 [EL 4]). Cytologic specimens that may be included in the benign class, even when the criteria for adequacy are not completely fulfilled, are those characterized by the presence of the following:

- (1) Generous and uniform colloid material, aspirated from lesions clearly described as cysts at US examination. These specimens should be defined as *consistent with fluid from a benign cystic colloid nodule*.
- (2) A dominant cellular population composed of variable size lymphocytes, in lesions with clinical and US diagnosis of Hashimoto thyroiditis (150 [EL 4],151 [EL 4-consensus],152 [EL 4]).

The risk of malignancy in benign lesions is reported as 0 to 3.7% (141 [EL 4]). These data are partially flawed by the small percentage (usually about 10%) of cytologically benign nodules that are submitted for surgical procedure, frequently on the basis of their growing size or clinical suspicious findings (141 [EL 4]). In centers with expertise in thyroid cytologic evaluation, the overall risk of malignancy of nodules benign at FNA is expected to be about 1% and decreases further with repeated FNA (152 [EL 4],153 [EL 3],159 [EL 3],160 [EL 3]).

**Thyroid 3. Indeterminate.** This category comprises a heterogeneous group of cytologic characteristics for which a definite cytologic diagnosis of benign or malignant thyroid lesion cannot be established on the basis of cytomorphic characteristics (141 [EL 4]). The prevalent pattern is represented by follicular-patterned specimens, but the group also includes samples with cellular atypia where FNA cytologic evaluation cannot reliably exclude cancer. These specimens correspond on histologic grounds to adenomatoid hyperplasia, follicular adenoma and carcinoma, Hürthle cell neoplasms, and the follicular variant of PTC (150 [EL 4],151 [EL 4-consensus],152 [EL 4]).

The widely used Bethesda System for Reporting Thyroid Cytopathology (BSRTC) subdivides indeterminate cytologic results into AUS/FLUS and the pure follicular patterned lesions, suggesting a follicular neoplasm (FN/SFN) (141 [EL 4]). This distinction separates 2 cytologic categories, at expected different risk of malignancy, to provide a tailored therapeutic approach. A similar subdivision was subsequently adopted by the UK Royal College of Pathologists (BTA-RCPATH), which defined the 2 subclasses as “neoplasm possible-atypia nondiagnostic (Thy 3a),” and “neoplasm possible-suggesting follicular neoplasm (Thy 3f),” respectively (see Table 2) (150 [EL 4]).

Some limitations of this subclassification have been demonstrated in clinical practice. The expected 5 to 15% risk of malignancy in the AUS/FLUS category was not consistently confirmed by subsequent studies, which reported either a similar (161 [EL 3]) or a higher (162 [EL 3],163 [EL 3],164 [EL 4]) risk in this class. Retrospective analysis demonstrated within the AUS/FLUS cohort the presence of high-risk cytologic subgroups with an increased probability of PTC. This unexpectedly elevated prevalence of malignancy may be due, at least in part, to the nodules with “mild/focal nuclear atypia” features that are included in the AUS/FLUS category but may be observed in the follicular

variant of PTC (162 [EL 3],163 [EL 3],165 [EL 3]). For this reason, and at variance with BSRTC and BTA-RCPATH, a subsequent classification system (152 [EL 4]) included cases with mild/focal nuclear atypia in the subcategory of indeterminate lesions at a higher risk of malignancy (defined as TIR 3B). Instead, follicular lesions that feature a relevant (about 30%) proportion of microfollicles but do not completely fulfill the diagnosis of follicular neoplasms were included in the subcategory TIR 3A, at an expected “lower risk of malignancy” (152 [EL 4]). Based on these considerations, we suggest subdividing the indeterminate cytology class into 2 subclasses: *low-risk indeterminate lesion* (AUS/FLUS) (of the BSRTC, Thy 3a of the BTA-RCPATH classification and, with minor differences, TIR 3A of the Italian classification system) and *high-risk indeterminate lesions* (corresponding to the pure follicular patterned lesions, defined as FN/SFN, Thy 3f, or TIR 3B of the BSRTC, BTA-RCPATH, or Italian classification system, respectively) (see Table 2) (150 [EL 4],151 [EL 4-consensus],152 [EL 4]).

**Thyroid 4. Suspicious for Malignancy.** This diagnostic category includes samples in which a cytologic diagnosis of malignancy is strongly suspected but cannot be established with full certainty (141 [EL 4]). PTC accounts for the majority of these cases (154 [EL 2]). Cytologic specimens showing only mild atypia should not be included in this category and should be classified in the indeterminate category (152 [EL 4]). In the absence of immunocytochemistry or other ancillary techniques, some cases of MTC or other malignancies may be occasionally included in this category (150 [EL 4],151 [EL 4-consensus]).

This category accounts for 2.5 to 5% of cytologic diagnoses (151 [EL 4-consensus]). The malignancy risk in this class is from 60 to 75% (154 [EL 2],159 [EL 3]).

**Thyroid 5. Malignant.** Malignant results include samples characterized by malignant cytologic features that are identified with certainty by the cytopathologist (141 [EL 4]). The most frequent malignant lesion encountered is PTC. Other malignant lesions include MTC, poorly differentiated and anaplastic carcinomas, lymphomas,

miscellaneous thyroid tumors, and metastatic cancers (156 [EL 4],157 [EL 4]).

The cytology report should contain a cytology description and, whenever possible, the diagnosis of the type of malignant tumor. Depending on the series, this category ranges from 4 to 5.4% of the cytology diagnoses, and the risk of malignancy is more than 95% (range, 95-99%) (154 [EL 2],159 [EL 3],160 [EL 2]).

#### 4.3. FNA Results: Efficacy and Limits

The result of FNA is critical when deciding whether to manage a nodule medically or surgically. Selection of patients for surgical treatment on the basis of FNA has considerably decreased thyroid surgery frequency and has increased the yield of cancer (166 [EL 3]). FNA provides a reliable cytologic diagnosis of thyroid nodules, but the final definition of the lesion is by histology only (152 [EL 4]). Thus, clinical management of the individual patient should always be based on cytologic features and all the available clinical, imaging, and laboratory findings (1 [EL 4-review],167 [EL 3]). The sensitivity and specificity of FNA, when performed by experienced personnel, are excellent. In a meta-analysis on 25,445 thyroid FNAs, 25% of which underwent surgery, the sensitivity, specificity, and diagnostic accuracy were 97.0%, 50.5%, and 68.8%, respectively. The PPV was 55.9% and the NPV was 96.3% (154 [EL 2]). The true prevalence of malignancy in the benign class can only be determined with difficulty because most benign diagnoses are managed conservatively. For palpation-guided FNA, the rate of a false-negative result—a missed diagnosis of malignant disease—has been reported in the past as high as 11% (1 [EL 4-review],8 [EL 4]). However, with the use of US-guided FNA, the rate of false-negative FNA results, established on clinical grounds, is about 1% (145 [EL 3],146 [EL 4],147 [EL 3],148 [EL 4],149 [EL 4],150 [EL 4],151 [EL 4-consensus],152 [EL 4],154 [EL 2],155 [EL 4],156 [EL 4],157 [EL 4],158 [EL 3],159 [EL 3],160 [EL 2],161 [EL 3]) and decreases further with repeated FNA (168 [EL 3],169 [EL 3]). A false-positive diagnosis implies that no malignancy is detected at histologic examination in a patient with a

**Table 6**  
Summary Characteristics for Thyroid FNA<sup>a</sup>

Feature	Range %	Definition
Sensitivity	88.2-97.0	Likelihood that patient with disease has positive test results
Specificity	47.0-98.2	Likelihood that patient without disease has negative test results
PPV	52.0-98.0	Fraction of patients with positive test results who have disease
NPV	89.0-96.3	Fraction of patients with negative test results who do not have disease
False-negative rate	0.5-10.0	FNA negative; histologic findings positive for cancer
False-positive rate	1.0-7.0	FNA positive; histologic findings negative for cancer

Abbreviations: FNA = fine-needle aspiration; NPV = negative predictive value; PPV = positive predictive value.

<sup>a</sup> Data from Bongiovanni et al, *Acta Cytol.* 2012;56:333-339; Piana et al, *Cytopathology.* 2010; Tee et al, *Ann Surg.* 246:714-720; Wang et al, *Thyroid.* 2011;21:243-251.

suspicious or frankly positive FNA. The reported prevalence of false-positive results ranges from less than 1 to 7.7% but is about 1% in institutes with specific expertise (150 [EL 4],151 [EL 4-consensus],152 [EL 4]).

Most errors result from an inappropriate sampling site, specimen inadequacy, overlapping features, degenerative changes, or cytopathologist inexperience (156 [EL 4],157 [EL 4]). Thus, in the case of equivocal cytologic findings, consider a second opinion from an experienced cytopathologist or a repeat sampling with FNA under US guidance.

#### 4.3.1. *Thyroglobulin and Hormone measurement on FNA*

The measurement of Tg levels in the needle washout (FNA-Tg) increases FNA accuracy of lymph nodes suspicious for metastasis from differentiated thyroid cancer, circumventing the occurrence on nondiagnostic cytologic results (170 [EL 3],171 [EL 3],172 [EL 3],173 [EL 3],174 [EL 2],175 [EL 3],176 [EL 2],177 [EL 3],178 [EL 4]). According to a recent meta-analysis including 24 selected studies, the overall FNA-Tg sensitivity and specificity are good, corresponding to 95.0% and 94.5%, respectively (179 [EL 2]). In most instances, metastatic lymph nodes show exceedingly high (e.g.,  $10^3$ - $10^6$  ng/mL) FNA-Tg levels, making the interpretation of results clear. Yet, the technique for FNA-Tg determination is not fully standardized because of the use of different saline volumes (from 1 to 3 mL) for sample dilution, as well as differences in the analytical performance of the commercially available Tg assays. As a consequence, a single validated FNA-Tg cutoff level for the diagnosis of lymph node metastasis of PTC is lacking, and different studies have proposed a variety of cutoff levels, ranging from 0.9 to 39.0 ng/mL (153 [EL 3],179 [EL 2],180 [EL 3],181 [EL 3],182 [EL 4],183 [EL 3]). Moreover, some factors may occasionally lead to false-negative FNA-Tg results—for example, the “hook effect,” which may affect the immunometric assays in the presence of increased concentrations of the analyte, dedifferentiation of the neoplastic tissue, and, according to some but not all studies (184 [EL 3],185 [EL 2]), the interference of anti-Tg antibodies. On the other hand, contamination of the cytologic sample with blood may induce false-positive results in patients with detectable/elevated serum Tg levels.

Analogous to FNA-Tg, calcitonin measurement in needle washouts (FNA-CT) can be used in enlarged lymph nodes of patients with MTC or in suspicious thyroid nodules of patients at risk for MTC or MEN2 syndrome (186 [EL 3],187 [EL 3],188 [EL 3],189 [EL 2]).

In patients with primary hyperparathyroidism, determination of parathyroid hormone (PTH) levels in the needle washout (FNA-PTH) is a valuable tool for a confirmation of the US localization of enlarged parathyroid glands (190 [EL 3],191 [EL 3],192 [EL 2],193 [EL 3],194 [EL 3],195 [EL 3]). As for Tg, the calcitonin and PTH assays have been validated for serum determination but not for saline washouts, and no consensus has been reached on

definite cutoff levels. The possibility of false-positive and false-negative results should always be considered before clinical action is taken. These determinations should be carried out in referral centers that have previously determined their own cutoff levels for these assays.

Calcitonin measurement on the FNA washout from suspicious thyroid nodules in patients at risk for medullary carcinoma or the MEN2 syndrome provides useful information (186 [EL 3]). However, because of the absence of a test validation, these data should be interpreted with caution in the confirmation of MTC.

#### 4.4. Core-Needle Biopsy

CNB, performed under US guidance with a 18- to 21-gauge cutting needle, may offer additional information to FNA results in cases of thyroid or neck lesions with repeatedly inadequate FNA (196 [EL 3]). In a recent retrospective series of 360 nodules (180 consecutive repeated FNAs and 180 consecutive CNBs) with initially nondiagnostic FNA, CNB provided a significantly lower rate of persistently nondiagnostic samples than repeat FNA (1.1% vs. 40.0%,  $P < .001$ ). Diagnostic performance with CNB was reported as better than repeated FNA, and the diagnostic surgery rate was lower after CNB (3.6% vs 16.7%,  $P = .047$ ) (197 [EL 2]).

In patients with suspected anaplastic tumors, thyroid lymphomas, pathologic lymph nodes, or other malignant neck diseases, CNB usually provides complementary information for the clinical management (151 [EL 4-consensus],198 [EL 3]).

In recent studies—mostly noncontrolled and based on a small series of patients—a possible use of CNB in nodules with indeterminate cytologic findings was suggested to distinguish benign nodules from follicular neoplasms (199 [EL 2],200 [EL 3]). Surgical confirmation or long-term follow-up of lesions classified as benign at CNB is lacking in most of these series.

In conclusion, US-guided CNB is suggested as a complementary tool for solid nodules with persistently inadequate cytologic results before performing diagnostic surgery. Its use in selected cases of cytologically indeterminate nodules was reported as promising but needs confirmation from large prospective, histologically verified series.

#### 4.5. Immunocytochemistry

Immunohistologic markers such as galectin-3 HBME-1, fibronectin-1, CITED-1, and cytokeratin-19, have been investigated to improve the differential diagnosis between benign and malignant thyroid nodules with indeterminate cytologic results (201 [EL 2],202 [EL 2],203 [EL 2],204 [EL 3],205 [EL 3]). These markers have barely been adopted in routine diagnostics because of the absence of method standardization, possible pitfalls, and clinically relevant overlap of the results between follicular adenomas and differentiated thyroid carcinomas (206 [EL 4],207 [EL 4]).

Currently, no single cytochemical marker is specific and sensitive enough to reach a conclusive diagnosis in FNA indeterminate samples. Yet, immunocytochemistry continues to be an easy and accessible technique for further definition of the morphologic diagnosis in several pathology units. The use of panels of immunocytochemical markers may, in some centers with specific experience, reach a sensitivity and specificity of up to 90% (208 [EL 4]). The main limitations of immunocytochemistry on cytologic smears are the number of slides, decoloration of previous stain, and difficult-to-access intracellular antigens.

#### 4.6. Molecular Testing

Of FNA biopsies, 10 to 25% yield an indeterminate result, with the risk of malignancy varying from 5 to 75% (typically 15-30%) depending on the indeterminate category of the BTA-RCPATH (151 [EL 4-consensus]), BSRTC (155 [EL 4]), or the Italian Consensus for Thyroid Cytology (152 [EL 4]).

This section focuses principally on nodules that are either categorized as a follicular lesion or neoplasm Class 3 according to AACE/AME or an atypia or follicular lesion of undetermined significance (AUS/FLUS or Thy 3a [see Section 7.6.3.2.1]) and follicular neoplasm or suspicious for follicular neoplasm (FN/SFN or Thy 3f [see Section 7.6.3.2.1]) according to BSRTC or BTA-RCPATH. Lesions categorized as “suspicious for malignancy” are referred to specifically as such.

When assessing the clinical usefulness of molecular testing, it must be appreciated that even the gold standard of thyroid histopathologic analysis is limited by variations in interpretation. Cibas et al (209 [EL 2]) reported a 9% disagreement among pathologists when categorizing excised thyroid nodules as benign or malignant under blinded conditions. The physician and patient need to be aware that because molecular testing is in its infancy, continued research that includes prospective multicenter studies to validate all of these tests used either singly or in tandem, as well as advances, may change the understanding of how best to use molecular markers in the clinical setting.

Routine morphologic cytology is the basis for any kind of (integrated) molecular FNA diagnostics (152 [EL 4]). The detection of *BRAF*, *NRAS*, *HRAS*, and *KRAS* point mutations and *PAX8/PPARG* and *RET/PTC* rearrangements, with the aim to identify (rule in) thyroid cancer (210 [EL 2], 211 [EL 2], 212 [EL 2], 213 [EL 2]) has been investigated by several groups, with overall reproducible results. Several large, prospective, multicenter studies have independently validated the utility of testing for markers in FNA samples with indeterminate cytologic characteristics (210 [EL 2], 211 [EL 2], 212 [EL 2], 213 [EL 2]). These studies found that a positive result carries a PPV of approximately 90% for predicting cancer. Clinical validation has not been performed for thyroid nodules smaller than 1 cm.

The rule-in approach is also feasible for routine air-dried FNA smears, offering several advantages over obtaining additional fresh FNA material (213 [EL 2]).

A proposed gene expression classifier (GEC) to rule out malignancy (214 [EL 2]) requires confirmation by independent studies without selection bias. A prospective, blinded, multicenter study employing a proposed gene expression classifier (GEC) with a sensitivity of 90% and a specificity of 53% found that a negative result (i.e., a benign gene expression profile) has an NPV of approximately 95% for cytologically AUS/FLUS and FN/SFN lesions (214 [EL 2]). For the given sensitivity and specificity, an NPV of 95% or higher requires a risk of malignancy to be 23% or less (214b [EL 4]). This is in keeping with at least one subsequently published study with a 33% cancer rate for indeterminate nodules that found a lower NPV (89.6%) than previously reported (215 [EL 2]). In the opinion of the authors of the present clinical practice guidelines, a benign gene expression profile is useful clinically when the NPV is approximately 95% or greater. Categorization of a nodule as suspicious by the mutation panel carries a reported cancer risk of only 38%, so clinicians and patients need to understand that this result does not establish a cancer diagnosis (214 [EL 2]).

The detection of a *BRAF* mutation has very high specificity for PTC. Therefore, its detection in FNA material can be followed by thyroidectomy without frozen section. Since *NRAS*, *HRAS*, and *KRAS* point mutations and *PAX8/PPARG* and, less frequently, *RET/PTC* rearrangements have also been detected in benign thyroid nodules with variable frequencies in different publications, their specificities for thyroid carcinomas are lower. However, molecular studies provide some evidence to classify *RAS* or *PAX8/PPARG* or *RET/PTC* rearrangement-positive nodules that are histologically benign as being potentially premalignant.

The current somatic mutations panel of the rule-in approach for indeterminate FNA clarifies only about 60% of indeterminate FNAs (210 [EL 2]). Therefore, there is an urgent need for further markers that can reliably identify the remaining malignant but currently mutation-negative lesions and, especially, the many benign nodules among the indeterminate FNAs (216 [EL 4]). Identification of malignant but currently mutation-negative cases is possible with extended mutation panels (217 [EL 3]). In this laboratory setting, the *TERT* promoter mutation was reported as highly prevalent in advanced thyroid cancers. In a differentiated thyroid carcinoma series, this finding was confirmed to be present both in PTCs and FTCs (218 [EL 2]). *TERT* mutational analysis on FNA, when available, may improve the diagnostic sensitivity of molecular testing on cytologic samples (219 [EL 2]). There are no long-term follow-up studies for either mutation-negative thyroid nodules or nodules classified as “benign” by a GEC.



**Recommendations: Thyroid Biopsy**

## 4.1 Thyroid FNA

- Combine clinical and US evaluation and, when appropriate, FNA results in the clinical management of thyroid nodules [BEL 2, GRADE A].
- Always perform US-guided FNA since cytologic diagnoses are more reliable and the nondiagnostic rates are lower than with palpation-guided FNA [BEL 2, GRADE A].

4.1.1. *Requisition form*

- Include all relevant clinical and US information [BEL 4, GRADE C].
- Include a rating of the US risk of malignancy based on an acknowledged US classification system [BEL 3, GRADE B].
- Use the following 3 US rating categories: high US risk, intermediate US risk, and low US risk [BEL 4, GRADE C].
- Clearly state the sampling site and technique and the number of submitted slides and/or other sampled specimens [BEL 3, GRADE B].

4.1.2. *Cytologic report*

- Include a brief description of cytologic findings and, when possible, a conclusive cytologic diagnosis [BEL 2, GRADE A].
- Identify the cytologic result by adding a rating of the risk of malignancy based on an established classification system for thyroid cytology [BEL 2, GRADE A].

## 4.2. Cytologic Diagnosis

- Define FNA results as either diagnostic (satisfactory) or nondiagnostic (unsatisfactory) [BEL 3, GRADE B].
- As a general rule, define the cytologic specimen as *diagnostic* when the sample contains a minimum of 6 groups of well-preserved thyroid epithelial cells consisting of at least 10 cells per group [BEL 3, GRADE B].
- Classify cytologic specimens characterized by marked atypia as *suspicious*, even in the absence of the required number of follicular cells for adequacy [BEL 3, GRADE B].
- Five diagnostic classes, with subdivision of indeterminate samples in 2 subclasses, are recommended for cytologic reports [BEL 2, GRADE A].
- Use the following reporting system for thyroid cytologic results:

**Thyroid 1. Nondiagnostic**

- Inadequate or insufficient
- Cystic: inadequate but consistent with a benign cystic lesion

**Thyroid 2. Benign****Thyroid 3. Indeterminate**

- Atypia or follicular lesion of undetermined significance (or a similar subclass in comparable cytologic classification systems, see Table 2).
- Follicular neoplasm or lesion suspicious for follicular neoplasm (or similar subclass in comparable cytologic classification systems, see Table 2).

**Thyroid 4. Suspicious for malignancy****Thyroid 5. Malignant**

[BEL 2, GRADE B]

## 4.3. FNA Pitfalls

- To decrease the risk of misleading cytologic results, consider the following:
  - False-negative results are usually due to inappropriate target selection or inadequate sampling.
  - False-positive results are usually due to specimens with suspicious, but not diagnostic, findings [BEL 4, GRADE D]
- For indeterminate cytologic findings, consider a second opinion from an experienced cytopathologist because some of these cases may, in high-volume thyroid cytopathology units, be reassessed as definitely benign or malignant [BEL 3, GRADE C].
- To decrease the risk of false-negative results, we recommend the following:
  - Routine use of FNA
  - Aspiration of at least 2 sites within the nodule
  - For multiple nodules, prioritize nodules to be sampled according to US findings
  - For cystic lesions, sample solid or vascularized areas with FNA and submit cyst fluid for cytologic examination
  - Review the slides with an experienced cytopathologist
  - Follow-up benign nodule(s) with US in 12 to 24 months
  - Repeat FNA in benign nodules with suspicious clinical or US findings
  - In large-sized thyroid lesions, sample peripheral and, if possible, solid areas to avoid fluid or necrotic zones [BEL 3, GRADE B]

4.3.1. *Thyroglobulin and hormone measurement on FNA washout*

- Measurement of Tg, calcitonin, or PTH levels on FNA washout of suspicious thyroid lesions or lymph nodes is recommended

when clinically appropriate [BEL 2, GRADE A].

- Each center should determine its own reference range for hormone measurement on FNA washout samples [BEL 3, GRADE B].

#### 4.4. Core-Needle Biopsy

- Consider the use of US-guided CNB in solid thyroid nodules with persistently inadequate FNA cytologic findings [BEL 3, GRADE C].
- Because of the limited evidence and lack of established reporting systems, we do not recommend either in favor of or against the use of CNB in nodules with indeterminate cytologic results [BEL 4, GRADE D].

#### 4.5. Immunocytochemistry

- Immunocytochemistry is suggested in lesions that are suspected of nonfollicular origin (e.g., parathyroid glands, medullary thyroid carcinomas, lymphomas, metastases from other organs) [BEL 3, GRADE B].

#### 4.6. Molecular Testing

Patient-specific characteristics, the prevalence of cancer within a given population, as well as the distribution and diagnostic accuracy for each cytologic classification have substantial impacts on assessing the odds of malignancy. This was highlighted in a 2012 meta-analysis showing that the malignancy rates across studies for AUS and FLUS ranged from 6 to 48% and 14 to 34%, respectively (154 [EL 2]). While molecular analysis of FNA genetic material from thyroid nodules shows great promise in refining the diagnosis, prognosis, and treatment of thyroid cancer, there are currently insufficient data to support a universal recommendation for molecular testing in the further categorization of “indeterminate” thyroid nodules.

##### 4.6.1. *When should molecular testing be considered?*

- To complement, not replace, evaluation [BEL 2, GRADE A]
- The results are expected to influence clinical management [BEL 2, GRADE A].
- As a general rule, molecular testing is not recommended in nodules with established benign or malignant cytologic characteristics [BEL 2, GRADE A].

##### 4.6.2. *Molecular testing for cytologically indeterminate nodules*

- Cytopathology expertise, patient characteristics, and prevalence of malignancy within the population being tested impact the NPVs and PPVs for molecular testing [BEL 3, GRADE B].
- Consider the detection of *BRAF* and *RET/PTC* and, possibly, *PAX8/PPARG* and *RAS*, mutations if such detection is available [BEL 2, GRADE B].

- Because of the insufficient evidence and the limited follow-up, we do not recommend either in favor of or against the use of GECs for cytologically indeterminate nodules [BEL 2, GRADE B].

##### 4.6.3. *Role of molecular testing for deciding the extent of surgery*

Currently, with the exception of mutations such as *BRAFV600E* that has a PPV approaching 100% for PTC, evidence is insufficient to recommend in favor of or against the use of mutation testing as a guide for the extent of surgery [BEL 2, GRADE A].

##### 4.6.4. *How should patients with nodules that are negative at mutation testing be monitored?*

- Since the false-negative rate for indeterminate nodules is 5 to 6% and the experience and follow-up for mutation-negative nodules or nodules classified as benign by a GEC are still insufficient, close follow-up is recommended [BEL 3, GRADE B].

## 5. Laboratory Evaluation

### 5.1. Thyroid Hormones

The high sensitivity of the TSH assay for detecting even subtle thyroid dysfunction makes it the most useful laboratory test in the initial evaluation of thyroid nodules (220 [EL 4-review]). Measuring serum levels of free thyroid hormones and TPOAb or TRAb should be the second diagnostic step, which is necessary for confirmation and the subsequent definition of thyroid dysfunction when the TSH concentration is outside the reference range (221 [EL 4-guidelines]).

Third-generation TSH chemiluminometric assays, with detection limits of about 0.01  $\mu\text{U/mL}$ , should be used. They can detect minute TSH levels and allow a reliable diagnosis of mild (subclinical) thyroid hyperfunction (220 [EL 4-review], 220b [EL 2], 220c [EL 2], 221 [EL 4-guidelines]).

If the serum TSH level is within the reference range (unless suspicion of central hypothyroidism), the measurement of free thyroid hormones adds no further relevant information. If TSH levels are low, however, measurement of  $\text{FT}_4$  and  $\text{FT}_3$  is necessary to confirm hyperthyroidism or consider central hypothyroidism, in which TSH concentration can be normal or low and  $\text{FT}_4$  levels may be low (222 [EL 4-review]).

To limit unnecessary laboratory testing, the following strategy should be followed for most patients with thyroid nodules (222 [EL 4-review], 223 [EL 4-review]):

- Serum TSH level within normal limits: no further testing (unless suspicion of central hypothyroidism)
- Increased serum TSH level: test  $\text{FT}_4$  and TPOAb to evaluate for hypothyroidism
- Decreased serum TSH level: test  $\text{FT}_4$  and total or  $\text{FT}_3$  to evaluate for hyperthyroidism

TPOAb should be measured in patients with above-normal levels of serum TSH (222 [EL 4-review],223 [EL 4-review]). High serum TPOAb values associated with a firm, diffusely enlarged, or more often atrophic small thyroid, are compatible with chronic autoimmune or Hashimoto thyroiditis (17 [EL 4],223 [EL 4-review],224 [EL 3]). Occasionally, a nodular goiter may also harbor Hashimoto thyroiditis (223 [EL 4-review]).

Tg antibody testing should be limited to patients who have US and clinical findings suggestive of chronic lymphocytic thyroiditis and with normal serum TPOAb levels (222 [EL 4-review]).

TRAb determination should be performed in patients with hyperthyroidism, for more complete clarification of etiologic factors (225 [EL 3]), because 17% of patients in iodine-deficient areas with scintigraphically toxic MNG test positive for TRAb (226 [EL 3]).

Assessment of serum Tg is not recommended in the diagnosis of thyroid nodules (223 [EL 4-review]). Testing of serum Tg was proposed before thyroid surgery for thyroid malignancy, so as not to overlook the rare cases of false-negative serum Tg value due to decreased Tg immunoreactivity or heterophilic antibodies (227 [EL 3],228 [EL 3]). However, its use is not recommended in routine clinical practice in the evaluation of thyroid nodules.

## 5.2. Calcitonin

### 5.2.1. Basal calcitonin

Calcitonin is a serum marker for MTC and correlates with tumor burden (229 [EL 3]). Medullary thyroid carcinomas are rare (230 [EL 3]), but serum calcitonin testing is strongly recommended in patients with a history of or clinical suspicion of familial MTC or MEN2 (230 [EL 3],231 [EL 4-guidelines]). Calcitonin may rarely be relevant in indeterminate or suspicious cytology to rule out MTC and in patients with a nodular goiter undergoing thyroid surgery to avoid the risk of incomplete surgery (230 [EL 3],232 [EL 2]).

Routine testing of serum calcitonin for MTC in unselected patients with thyroid nodules is controversial (233 [EL 3],234 [EL 4-guidelines]). Based on many nodular thyroid disease studies, the prevalence of MTC ranges from 0.4% to 1.4% (230 [EL 3],232 [EL 2]). Calcitonin levels can also be increased in patients with nonthyroidal pathologic findings such as pulmonary or pancreatic endocrine tumors, kidney failure, autoimmune thyroid disease, or hypergastrinemia (resulting from proton-pump inhibitor therapy). Other factors that increase calcitonin values are alcohol consumption, smoking, sepsis, and heterophilic anticalcitonin antibodies. In addition, sex, age, weight, increased calcium levels, and the assay itself also affect the calcitonin levels. Cross-reactivity with procalcitonin must be excluded (235 [EL 3], 236 [EL 3], 237 [EL 3]).

Cutoff values such as 15 or 20 or 18.7 pg/mL in females and 6 to 8 pg/mL in males, have been used to select unselected nodules (232 [EL 2],238 [EL 3]), whereas

there is no description of tumors >0.5 cm and lymph node metastasis when the basal calcitonin is 30 to 60 pg/mL. A single nonstimulated calcitonin measurement may be considered in the work-up of thyroid nodules with suspicious US or cytologic findings with the above caveats taken into account. If the basal calcitonin value is increased, the test should be repeated, and if confirmed in the absence of the above modifiers, a calcium-stimulation test is recommended to increase the diagnostic accuracy in patients with a basal calcitonin value <100 pg/mL (232 [EL 2]). A histologically controlled study of 91 patients with nodular goiter or MTC was performed with a 2-site chemiluminescent assay that had analytical sensitivity of 2 pg/mL (238 [EL 3],239 [EL 3]). The basal calcitonin cutoff points that were able to separate non-MTC patients (with both goitrous and C-cell hyperplasia) from MTC were 26 and 68 pg/mL in females and males, respectively.

### 5.2.2. Calcium-stimulated calcitonin

Because pentagastrin is limited in Europe and unavailable in the U.S., calcitonin stimulation should be performed with calcium, which has better tolerance and a similar diagnostic efficacy (239 [EL 3],240 [EL 2]). The specific calcium-stimulated calcitonin values that distinguish nodular goiters from MTC patients are still under evaluation (239 [EL 3],241 [EL 3]). Calcium gluconate (25 mg or 2.3 mg of elemental calcium/kg of ideal body weight) is given intravenously after a 4-hour fast. Calcitonin is determined before and 2, 5, and 10 minutes after calcium gluconate injection (239 [EL 3],240 [EL 2]). Potential adverse effects are flushing, feeling of warmth, and facial paresthesias or altered gustatory sensation (240 [EL 2]). Because rare cases of sinus bradycardia have been described (241 [EL 3]), the test should not be performed in patients with sinus bradycardia, atrioventricular block, or electrolyte imbalance. Due to 1 reported episode of cardiac arrest, calcium infusion should be performed with cardiac monitoring (240b [EL 3]).

Proposed threshold values for MTC are 79 and 574 pg/mL for females and males, respectively. These cutoff levels are similar to those recommended for pentagastrin-stimulated calcitonin and show a good correlation with basal threshold values (239 [EL 3],241 [EL 3]).

### 5.2.3. Genetic screening

Genetic screening of at-risk family members should be done by testing for germline mutations in the *RET* proto-oncogene (138 [EL 4],242 [EL 3],243 [EL 4]). Such a screening in apparently sporadic MTC may detect MEN2 in about 5% of cases.

## Recommendations: Laboratory Evaluation

### 5.1. Thyroid Hormones

- Always measure serum TSH [BEL 1, GRADE A].
- If TSH level is decreased, measure FT<sub>4</sub> and total or FT<sub>3</sub>; if TSH level is increased, measure FT<sub>4</sub> and TPOAb [BEL 1, GRADE A].

- Test for Tg antibody in patients with US or clinical findings suggestive of chronic lymphocytic thyroiditis, when serum levels of TPOAb are negative [BEL 3, GRADE B].
- Assessment of serum Tg is not recommended in the diagnosis of thyroid nodules. In patients undergoing surgery for cancer, a preoperative serum Tg measurement may be considered [BEL 2, GRADE C].
- Perform TRAb measurement only in patients when Graves' disease is suspected [BEL 3, GRADE C].

### 5.2. Calcitonin

- We do not recommend either in favor of or against the routine determination of serum calcitonin in the evaluation of thyroid nodules [BEL 3, GRADE D].
- Determine serum calcitonin in thyroid nodules with US findings or indeterminate cytologic findings suggestive of MTC [BEL 3, GRADE B].
- Obtain serum calcitonin level in patients with a family history or clinical suspicion of MTC or MEN2 [BEL 2, GRADE A].
  - If basal calcitonin level is increased, repeat the test in the absence of possible modifiers [BEL 2, GRADE A].
- If an elevated (<100 pg/mL) calcitonin level is confirmed, perform a calcium stimulation test to increase the diagnostic accuracy [BEL 3, GRADE C].
- Due to a lack of availability, pentagastrin stimulation is no longer recommended [BEL 3, GRADE C].

### 5.3. Other Tests

- Measure serum calcium and PTH when a nodular lesion is suspicious for parathyroid adenoma [BEL 3, GRADE B].

## 6. Radionuclide Scanning

### 6.1. When to Perform Thyroid Scintigraphy

Thyroid scintigraphy is the only technique that allows assessment of regional thyroid function and AFTN detection (139 [EL 4]).

On the basis of the pattern of radionuclide uptake, nodules may be classified as hyperfunctioning (hot), hypofunctioning (cold), or indeterminate (139 [EL 4]). Hot nodules almost never represent as clinically significant malignant lesions, whereas cold or indeterminate nodules have a reported malignancy risk of 3% to 15% (244 [EL 3],245 [EL 4-review]).

Because most thyroid lesions are cold or indeterminate and only some of them are malignant (246 [EL 3],247 [EL 3]), the predictive value of hypofunctioning or indeterminate nodules for the presence of malignancy is low. The

diagnostic specificity is further decreased in small lesions (<1 cm) that are below the scintigraphy resolution threshold (139 [EL 4]).

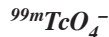The role of scintigraphy in the diagnostic work-up of thyroid nodules is limited in countries with iodine-rich diets in which serum TSH measurement and thyroid US can correctly diagnose autonomous nodules in most patients (244 [EL 3],245 [EL 4-review]), and FNA facilitates the accurate diagnosis of a malignant lesion. Moreover, because US resolution is considerably greater than that of scintigraphy, radionuclide scanning has little place in the topographic assessment of nodular goiter and no place in thyroid nodule measurement. However, when thyroid nodules are present in patients with Graves' disease, a radionuclide scan should be used to rule out the possibility of a cold thyroid nodule within a hyperfunctioning gland.

In geographic regions with iodine deficiency, thyroid scintigraphy is used as part of the evaluation of patients with MNG (246 [EL 3]) because it provides useful information on the functional characterization of thyroid nodules. It allows early diagnosis of thyroid autonomy and prioritization of cold and indeterminate nodules in MNGs for FNA biopsy (139 [EL 4]). In patients from these regions, serum TSH may remain unsuppressed even when autonomy is present because of the low proliferation rate of thyroid epithelial cells and the low synthesis rate of thyroid hormones by iodine-depleted thyroid glands (247 [EL 3]). Moreover, the bulk of autonomous tissue may be insufficient to suppress the TSH level in the early phases of autonomy (247 [EL 3],248 [EL 3]). The early recognition of autonomous nodules—before they induce TSH suppression—enables early treatment to avoid thyroid growth and progression toward manifest hyperthyroidism (249 [EL 3]). Furthermore, in iodine-deficient euthyroid goiters, microscopic areas of hot thyroid tissue contain constitutively activating TSH receptor mutations that increase the risk of iodine-induced hyperthyroidism (249 [EL 3]).

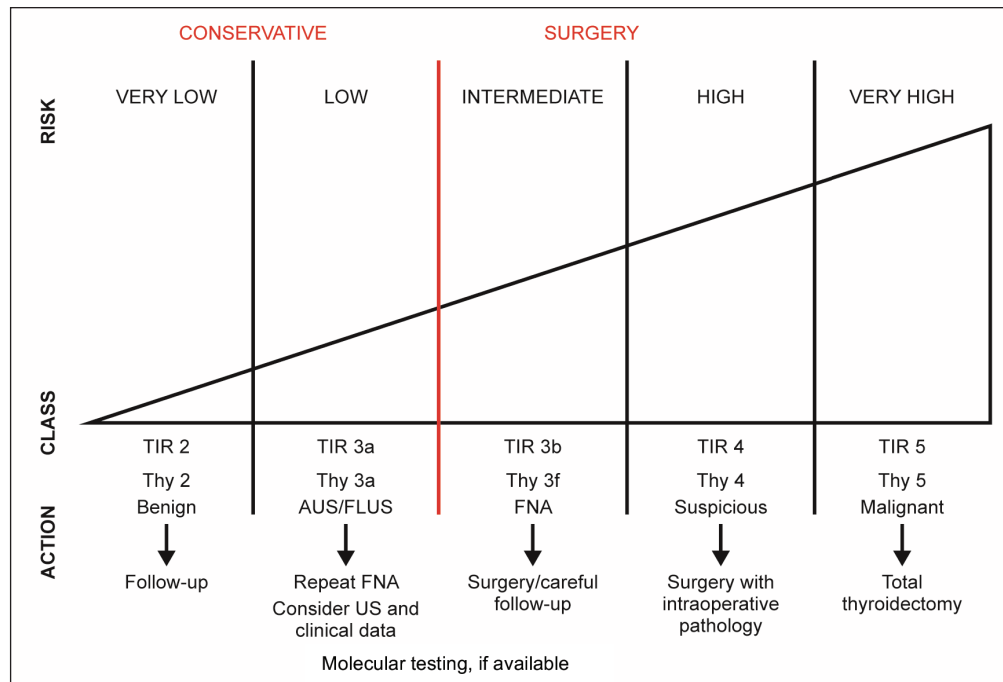
### 6.2. How to Perform Thyroid Scintigraphy

Quantitative pertechnetate scintigraphy (calculation of technetium thyroid uptake under suppression) is a sensitive and specific technique for the diagnosis and quantitation of thyroid autonomy and is a reliable predictor of hyperthyroidism in the clinical setting of euthyroid autonomy (139 [EL 4]).

Thyroid scintigraphy can be performed with  $^{123}\text{I}$  or  $^{99\text{m}}\text{TcO}_4^-$  (sodium pertechnetate). Each of these imaging agents has advantages and disadvantages.



- Advantages: less expensive, more readily available, more rapid examination
- Disadvantages: technetium is trapped but not organified (risk of false-positive images), activity in the esophagus or vascular structures can be misleading, and image quality is poor when uptake is low



**Fig. 3.** Cytologic categories and suggested clinical actions. AUS/FLUS indicates follicular lesion/ atypia of undetermined significance. *FNA* = fine-needle aspiration; *TIR* = Thyroid Imaging Reporting; *Thy* = thyroid; *US* = ultrasonography.

### <sup>123</sup>I

- Advantages: better visualization of retrosternal thyroid tissue, better images when thyroid uptake is low, real iodine clearance of the thyroid may be measured instead of technetium uptake, as a surrogate parameter
  - Disadvantages: higher cost, less comfortable for the patient (delayed imaging at 24 hours is often used), less readily available, imaging times usually longer
- Thyroid scintigraphy is indicated in the following settings:
- FNA biopsy is not necessary for hot nodules with a single thyroid nodule and suppressed TSH level
  - In MNGs, even without suppressed TSH, to identify cold or indeterminate areas for FNA biopsy, and hot areas that do not need cytologic evaluation
  - In large MNGs, especially with substernal extension
  - In the diagnosis of ectopic thyroid tissue, such as sublingual thyroid
  - In subclinical hyperthyroidism to identify occult hyperfunctioning tissue
  - In follicular lesions at FNA cytologic evaluation, to identify a functioning nodule that may be benign; however, most such nodules are cold on scintigraphy
    - To determine eligibility for radioiodine therapy
    - To distinguish low-uptake from high-uptake thyrotoxicosis

### Recommendations: Radionuclide Scanning

#### 6.1. When to Perform Thyroid Scintigraphy

- In a thyroid nodule or MNG, when the TSH level is below the lower limit of the reference range or when ectopic thyroid tissue or a retrosternal goiter is suspected [BEL 2, GRADE A]
- In iodine-deficient regions, to exclude autonomy of a thyroid nodule or MNG even when the TSH level is low-normal [BEL 2, GRADE B]
- Independent of the TSH level and whether in iodine-deficient or -sufficient regions, to evaluate eligibility for radioiodine therapy [BEL 2, GRADE B]

#### 6.2. How to Perform Thyroid Scintigraphy

- Use of <sup>123</sup>I or <sup>99m</sup>TcO<sub>4</sub><sup>-</sup> can be considered for thyroid scintigraphy [BEL 3, GRADE C].
- Sodium iodide <sup>131</sup>I thyroid uptake is not recommended for routine diagnostic use unless low-uptake thyrotoxicosis is suspected [BEL 3, GRADE C].

### 7. Management and Therapy

Clinical management of thyroid nodules should be guided by clinical data, together with the results of US evaluation and FNA cytologic analysis, if appropriate (60

[EL 4],167 [EL 3]) (Fig. 1 through 3). Interdisciplinary consultation and personal decision-making jointly with the patient are strongly advised in uncertain cases (61 [EL 4]).

#### 7.1. Nodules Nondiagnostic by FNA

Nondiagnostic FNA specimens usually result from cystic nodules that yield few or no follicular cells; benign or malignant sclerotic lesions; nodules with a thick or calcified capsule; abscesses; and hypervascular or necrotic lesions (156 [EL 4],157 [EL 4]). Frequent additional causes of nondiagnostic results may be sampling error or inadequate biopsy technique (158 [EL 3]).

Reaspiration yields satisfactory results in more than 50% of cases (157 [EL 4],250 [EL 3]). In a series of 595 nondiagnostic nodules, a repeat FNA provided a final benign result in 58.5%, an indeterminate in 9%, and a suspicious-for-malignancy in 11.8% of cases (159 [EL 3]). The optimal timing of repeat FNA has not been established, but a waiting period of at least 1 month before reaspiration is suggested to avoid biopsy-induced reactive changes (251 [EL 3],252 [EL 4]). However, if suspicious US findings are present or the clinical suspicion of malignancy is high, the procedure may be repeated without a delay (152 [EL 4]). Despite adequate initial technique and repeat biopsy under US guidance, up to 10% of nodules in most series continue to be nondiagnostic because of factors inherent to the lesion (154 [EL 2],157 [EL 4],159 [EL 3]). In nondiagnostic specimens, the reported malignancy rate is from 2 to 16% (154 [EL 2],157 [EL 4],159 [EL 3],250 [EL 3]). Notably, the rate of persistently nondiagnostic results is higher in thyroid cysts and in dominantly cystic (fluid component, >50%) thyroid lesions (250 [EL 3]).

On this basis, nondiagnostic aspirates composed of pure colloid and obtained from a nodule that is completely or primarily cystic (>50%) on US should be labeled as compatible with a colloid cyst and require only clinical and US follow-up (150 [EL 4],151 [EL 4-consensus],152 [EL 4]). Aspirates of complex lesions containing only blood, necrotic debris, and iron-laden histiocytes are probably hemorrhagic cysts, but they need careful correlation with clinical and US findings and follow-up (152 [EL 4],167 [EL 3]).

Solid, persistently nondiagnostic nodules should be considered for US-guided CNB (198 [EL 3]) because microhistologic assessment may offer additional information to FNA in these cases (197 [EL 2],253 [EL 3]). Alternatively, nodules with favorable clinical and US findings can be monitored with surveillance at 6- to 12-month intervals, whereas suspicious lesions should be resected surgically (60 [EL 4],61 [EL 4]).

### 7.2. Nodules Benign by FNA

#### 7.2.1. Follow-up

Thyroid nodules with benign cytologic findings and no clinical or US risk factors should be followed-up clinically if they are asymptomatic (60 [EL 4],61 [EL 4],234

[EL 4-guidelines]). In most cases, clinical and US examination and TSH measurement are appropriate in 12 to 24 months, dependent on the clinical features and nodule volume growth (60 [EL 4]). In patients with stable US features and size, subsequent clinical controls may be performed at 2-year intervals.

As a general rule, routine repeat FNA is not necessary because of its low upgrading diagnostic value (168 [EL 3],254 [EL 2]). Cytologic assessment should be repeated for patients with initially benign cytologic results, but suspicious US findings, because of the low (about 1%-2%) but nonnegligible possibility of false-negative results (154 [EL 2],159 [EL 3],169 [EL 3]). Reaspiration under US guidance should be performed when a nodule shows suspicious US changes, enlarges substantially, or becomes symptomatic (60 [EL 4],234 [EL 4-guidelines]). A series of thyroid nodules benign at FNA cytologic evaluation and followed-up for a mean period of 3 years showed false-negative results in less than 1.5% of cases, which were mostly characterized by suspicious US findings (255 [EL 3],256 [EL 2]). A minority of benign thyroid nodules—about 11% to 15% over 5 years (25 [EL 2],56 [EL 1])—present with progressive growth, but their volume increase should be considered as an appropriate reason for repeat FNA only when the increase is more than 50% over 12 months (62[EL 4],234 [EL 4-guidelines]).

In asymptomatic patients with repeated benign FNA and with no suspicious US findings, the false-negative rate is extremely low and routine follow-up may be obviated.

#### 7.2.2. Medical treatment for benign nodules

Routine LT<sub>4</sub> suppressive therapy for an FNA-benign nodule is not recommended. A clinically significant (>50%) decrease in nodule volume is reported with LT<sub>4</sub> therapy only in a minority of patients (257 [EL 1]), especially in small nodules with colloid features at FNA and in iodine-deficient regions (258 [EL 2]). In the same areas, this favorable effect appears more convincing with the concomitant administration of iodine supplements (259 [EL 1]).

Long-term TSH suppression may prevent an increase in the size of a thyroid nodule and of the thyroid gland itself (259 [EL 1],260 [EL 1]), but nodule regrowth occurs after cessation of therapy; thus, commitment to long-term therapy seems inevitable. TSH-suppressive therapy with LT<sub>4</sub> is reported as not useful for prevention of goiter recurrence after lobectomy in patients with normal TSH levels by most (261 [EL 2],262 [EL 4]) even if not all prospective studies (262b [EL 2]). Moreover, sustained subclinical hyperthyroidism is associated with a decrease in bone density in postmenopausal females (263 [EL 1],264 [EL 1]) and an increase in major osteoporotic fractures (265 [EL 2]). The risk of atrial fibrillation is higher in elderly patients with suppressed TSH levels (266 [EL 2],267 [EL 2]), and overall morbidity appears increased (268 [EL 2]), as is the mortality rate (268 [EL 2],269 [EL 2]). So, a large

proportion of patients are ineligible for LT<sub>4</sub> therapy (270 [EL 3]).

It has recently been reported that lower serum TSH levels, induced by both thyroid autonomy and LT<sub>4</sub> treatment, are associated with a reduced risk of clinically detectable thyroid cancer (31 [EL 3],271 [EL 3]). These studies are not prospective, and their value in practice remains to be determined. Based on the above information, LT<sub>4</sub> treatment in patients with nodular thyroid disease is discouraged. It may be considered in association with iodine supplementation only in young patients who live in iodine-deficient geographic areas who have small nodular goiters with no evidence of functional autonomy.

An appropriate LT<sub>4</sub> substitution therapy should be considered in patients with nodular goiter and subclinical hypothyroidism.

#### 7.2.3. *Surgical indications for benign nodules*

When related to a thyroid nodule, the following symptoms are possible indications for surgical treatment: neck pressure, dysphagia, globus sensation, shortness of breath (especially when in the supine position), dyspnea on exertion, and pain (2 [EL 4-review]). The appearance of sudden and persistent dysphonia should prompt a rapid surgical consultation (61 [EL 4]).

It is important to verify that the symptoms are caused by the nodular thyroid and not related to other diseases such as pulmonary or cardiac disease; esophageal disorders; or other head, neck, or lung tumors (1 [EL 4-review]). If a thyroid nodule undergoes a suspicious change in its US features or increases in volume and becomes symptomatic, surgical resection should be considered despite benign FNA results (1 [EL 4-review],2 [EL 4-review]). Accordingly, for benign nodules >4 cm, surgery should be considered given the higher incidence of neoplastic disease present in large and progressively growing nodules.

A symptomatic uninodular goiter or an MNG, whether euthyroid or hyperthyroid, may be treated surgically or with radioiodine. The preferred extent of resection is lobectomy plus isthmectomy for benign uninodular goiter and (near) total thyroidectomy for MNG (272 [EL 4]), with a traditional approach or a video-assisted technique (273 [EL 4-review],274 [EL 4]). In elderly or fragile patients and those who decline surgery, nonsurgical, US-guided, minimally invasive techniques represent effective alternative therapeutic options (275 [EL 4],276 [EL 4]).

Surgery may be performed with minimal surgical risks in patients with thyroid nodules that are benign by FNA but become symptomatic (234 [EL 4-guidelines]). However, the cost of surgery, the frequent need for life-long substitution therapy, and the risk of complications, even when low, continue to be relevant concerns. Thus, in recent years, nonsurgical image-guided, minimally invasive treatments have been proposed for outpatient management of benign but symptomatic thyroid nodules (275 [EL 4],276 [EL 4]).

#### 7.2.4. *Percutaneous ethanol injection for benign nodules*

Cystic and complex thyroid lesions. Percutaneous fluid drainage may cure thyroid cysts; however, recurrence is common, and surgery is often the final treatment of large relapsing lesions (277 [EL 1]). Prospective randomized trials and long-term studies have shown that PEI is significantly superior to aspiration alone for inducing volume reduction in cysts and complex nodules with a dominant fluid component (278 [EL 3],279 [EL 1]). Volume reduction is followed by improvement of local pressure symptoms (275 [EL 4]). The recurrence rate of cystic lesions successfully treated with PEI is low, but several sessions may be necessary for large or multilocular thyroid cysts (85 [EL 2]). Hence, PEI seems especially suitable for medium-sized relapsing lesions that can effectively be treated with a single or few sessions. The procedure is rapid, safe, and well-tolerated and requires neither posttreatment observation nor medical support. Thyroid function is unaltered, and there is no induction of thyroid autoimmunity. For these reasons, PEI represents the first-line treatment of relapsing benign cystic lesions.

Hyperfunctioning thyroid nodules. In these nodules, short-term volume reduction is noted satisfactory (280 [EL 3]); however, long-term follow-up shows that a few years after PEI, serum TSH becomes suppressed in most cases (85 [EL 2]). PEI is generally not indicated for hyperfunctioning nodules or nodular goiters because of the high recurrence rate and should be reserved for hot nodules with compressing symptoms only when more effective alternative treatment options are not possible (275 [EL 4],276 [EL 4]).

Clinically significant decreases in nodule size after PEI have been reported in solid thyroid nodules that are cold on scintigraphy (281 [EL 3],282 [EL 1]). However, the response is less impressive than in cysts; repeat treatment is often needed, and adverse effects are more frequent (85 [EL 2]). For these reasons, PEI should be considered for benign solid nodules only when alternative and more efficacious treatment modalities are not available.

#### 7.2.5. *Imaged-guided thermal ablation for benign nodules*

In recent years, US-guided minimally invasive techniques have gained wide acceptance and dissemination as nonsurgical procedures for volume reduction of large thyroid nodules and improvement of local pressure and/or cosmetic symptoms (276 [EL 4]).

Laser ablation. US-guided laser thermal ablation (LTA) is performed with the insertion, using US-guidance, of fine (21-gauge) spinal needles into the target nodule (283 [EL 3]). Energy is delivered by means of 300-nm optical fibers from an NdYAG or diode laser to the lesion, on average during approximately 10 minutes. In most cases, a single treatment with 1 or 2 fibers induces a clinically significant

decrease in nodule volume and the amelioration of local symptoms (284 [EL 2],285 [EL 3]). LTA is performed with local anesthesia as an outpatient procedure. Clinical and US control should be performed 1 hour after laser treatment, even if adverse effects are rare (286 [EL 1]). Over-the-counter analgesics may be given for persistent local pain if needed (275 [EL 4]). Clinical and US examination may subsequently be performed at 1 and 12 months.

Several noncontrolled studies and 2 randomized trials have confirmed the tolerability, safety (major complications such as severe pain or recurrent nerve palsy are rare and transient), and clinical efficacy (287 [EL 1],288 [EL 2]) of LTA. A multicenter prospective randomized trial in euthyroid patients with cold nodules who were assigned to a single LTA session or to follow-up demonstrated a mean 57% volume decrease after LTA (286 [EL 1]), based on a nodule reduction of >50% in >65% of cases, which remained stable over 3 years. Local symptom complaints were reduced from 38% to 8% of patients, and cosmetic complaints from 72% to 16% of cases.

Available evidence shows that LTA is a well-tolerated and effective procedure for the persistent reduction of large benign nodules. No long-term influence on thyroid function or autoimmunity has been reported. The efficacy and tolerability of the procedure are similar across performing centers given adequate expertise and a dedicated training period (286 [EL 1]).

**Radiofrequency ablation.** Radiofrequency ablation (RFA) induces thermal injury to the nodule through a high-frequency alternating electric current (289 [EL 4]). Two types of electrodes are used for RFA of thyroid nodules: a multitined expandable electrode (14-gauge with 4-9 expandable hooks) and a straight, internally cooled electrode (17- or 18-gauge) (290 [EL 3],291 [EL 2]). The procedure can be performed on an outpatient basis. Conscious sedation is obtained with intravenous diazepam, and local anesthesia with lidocaine or ropivacaine is offered through subcutaneous pericapsular infiltration. A straight, internally cooled, short (7-cm) 18-gauge electrode needle with active tips of various sizes is the most appropriate for thyroid nodule ablation (289 [EL 4]) that is performed according to the “moving shot” technique: the nodule is divided into multiple virtual areas and thereafter is ablated unit by unit by moving the electrode tip (292 [EL 3]). The maneuver is repeated, without retreating from the nodule, until all areas are ablated. The ablation is confirmed by the appearance of a hyperechogenic area—due to microbubbles—and the abrupt increase of impedance (the so-called break point) registered on the radiofrequency generator monitor.

A recent meta-analysis showed a statistically significant improvement, including reduction in nodule size and improvement of both symptoms and cosmetic scores (293 [EL 1]). Improvement in nodule size remained significant in both hot and cold nodule subgroups. Twelve adverse

events were identified across all studies from a total of 306 treatments.

No study has compared RFA with surgical or other nonsurgical treatment modalities. A meta-analysis compared studies performed with LTA and RFA and showed higher efficacy in nodule size reduction with RFA (294 [EL 1]), but a recent large scale study on over 1,500 patients demonstrated that LAT induces a volume reduction similar to that reported with RFA (294b [EL 3]).

Altogether, the procedures described above may offer a less expensive and less invasive alternative to thyroid surgery, without the risks of subsequent cutaneous scar or hypothyroidism, for patients with steadily growing benign thyroid nodules who warrant treatment for cosmetic reasons or local symptoms.

#### 7.2.6. Radioiodine therapy

Radioiodine is indicated for the treatment of hyperthyroidism caused by a hyperfunctioning nodule or a toxic MNG (295 [EL 4]). The aims of radioiodine treatment are ablation of the autonomously functioning areas, restoration of euthyroidism, and reduction of goiter size (296 [EL 4-guidelines],297 [EL 3],298 [EL 4-guidelines]). AFTNs are usually more radioresistant than toxic diffuse goiters, and greater radiation doses may be needed for successful treatment, especially in countries with iodization programs leading to decreased radioactive iodine uptake (225 [EL 3],299 [EL 3]).

Radioiodine therapy normalizes thyroid function in 85 to 100% of patients with hyperfunctioning thyroid nodules or toxic MNGs (295 [EL 4]). After treatment, the thyroid volume generally decreases substantially (median decrease, 35% at 3 months and 45% at 24 months) (297 [EL 3],300 [EL 2]). Radioiodine treatment is generally thought to be effective and safe. Although some investigators have indicated that radioiodine treatment may be associated with increased cardiovascular and cancer death (301 [EL 2]), other large-scale epidemiologic studies have demonstrated discordant results (302 [EL 3]). Based on recent data, both increased morbidity (303 [EL 2]) and mortality (268 [EL 2]) rates are more likely related to the disease rather than its therapy.

After ablation of the autonomous tissue, most patients become euthyroid because of residual normal thyroid tissue, which is no longer suppressed. Nevertheless, depending on the dose of radioiodine used, follow-up of thyroid function, and the possible presence of autoimmune thyroiditis, postradioiodine hypothyroidism may develop in up to 60% of patients after 20 years (295 [EL 4],304 [EL 3]). In up to 5% of patients, immunogenic hyperthyroidism may result from radioiodine treatment of toxic or nontoxic nodular goiter (305 [EL 3],306 [EL 3]) because of induction of TRAbs (307 [EL 3]), typically occurring 3 to 6 months after radioiodine treatment.

Ingestion of drugs with high iodine content (e.g., amiodarone, a saturated solution of potassium iodide) should



be avoided before radioiodine administration so as not to impair radioiodine uptake by the thyroid. If possible, anti-thyroid drugs (especially propylthiouracil) (308 [EL 2]) should be withdrawn at least 1 week before treatment to prevent radioiodine uptake by normal thyroid tissue and increase uptake in the hot thyroid tissue. Use of antithyroid drugs during the first week after radioiodine therapy also decreases radioiodine treatment efficacy. However, it also decreases biochemical and clinical hyperthyroidism and complications such as atrial fibrillation (309 [EL 1]).

Radioiodine treatment is best suited for small- to medium-sized benign goiters, for patients previously treated surgically, those with serious comorbid conditions, and those who decline surgery (295 [EL 4]). However, radioiodine is not suited for large nodules that require high doses of radioiodine and that may be unresponsive to treatment or for situations when immediate resolution of hyperthyroidism is desired (295 [EL 4]). The only absolute contraindications to radioiodine treatment are breastfeeding and pregnancy, which should be excluded by a pregnancy test (295 [EL 4], 297 [EL 3], 298 [EL 4-guidelines]). There is no consensus on a lowest age limit for receiving radioiodine treatment (310 [EL 2]).

The use of radioiodine for the treatment of nontoxic nodular goiter has been reported in numerous studies from geographic areas with relatively low to high-normal dietary intake of iodine (223 [EL 4-review], 295 [EL 4], 311 [EL 3], 312 [EL 4]). No studies comparing radioiodine therapy given with or without dietary iodine restriction have been published.

In general, a 40 to 50% decrease in thyroid size after 1 year (295 [EL 4], 311 [EL 3], 313 [EL 3], 314 [EL 1]) and a 50 to 60% decrease after 3 to 5 years can be achieved with radioiodine therapy (315 [EL 4-review]), half of which is seen within 3 months (295 [EL 4]). The degree to which goiter volume decreases varies greatly, and 20% of patients do not seem to respond at all. In a randomized study (314 [EL 1]),  $LT_4$  had no effect, whereas radioiodine decreased goiter size by 50% after 1 to 2 years. In very large goiters (>100 mL), volume decreased by only 30 to 40% after 1 year, and the amount of decrease inversely correlated with initial goiter size (316 [EL 4], 317 [EL 3]). Theoretically, the effect of radioiodine depends on the retained dose in the thyroid. Radioiodine activities have generally been adjusted according to radioiodine uptake, aiming at an absorbed dose of 100 Gy (295 [EL 4], 302 [EL 3], 316 [EL 4]), but investigators have questioned whether this adjustment is worthwhile (318 [EL 3]). Because of regulations regarding allowed radiation doses, which vary considerably between countries, many physicians use fixed doses limited to the maximum outpatient activity to avoid hospitalization. Use of radioiodine usually improves symptoms and respiratory function (316 [EL 4], 317 [EL 3], 318 [EL 3], 319 [EL 2]).

Early adverse effects of radioiodine are generally mild and transient (295 [EL 4], 312 [EL 4]). They include radiation thyroiditis in approximately 3% of cases, transient thyrotoxicosis in 5%, and occasionally an increase in thyroid size of up to 25%. Late adverse effects are currently limited to hypothyroidism in 22 to 58% of cases within 5 to 8 years after therapy. Although the risk of malignancy is not generally thought to be increased, no large-scale studies have been conducted in patients with nontoxic goiter as opposed to toxic goiter. No studies have compared radioiodine therapy with surgery, and there are few quality-of-life studies using a validated thyroid-specific quality-of-life questionnaire (320 [EL 2], 321 [EL 2], 322 [EL 4]).

The use of recombinant human TSH (rhTSH) for nontoxic goiter is currently off-label. The main reason for using rhTSH is based on a desire to increase radioiodine uptake in the large number of patients with low uptake and to decrease extrathyroidal radioiodine uptake, thereby decreasing the risk of malignancy and facilitating a decrease in goiter size (295 [EL 4], 312 [EL 4], 323 [EL 1]).

The optimal dose of rhTSH and its timing in relation to subsequent radioiodine therapy are not clear. Recent data, however, suggest that radioiodine uptake is doubled with use of rhTSH doses as small as 0.03 to 0.1 mg without an evident dose-response relationship (295 [EL 4], 324 [EL 4-review]). Activation of the thyroid sodium-iodine symporter takes time, and an interval of 24 to 48 hours between rhTSH stimulation and radioiodine administration seems optimal (295 [EL 4], 312 [EL 4], 323 [EL 1]).

When used in combination with radioiodine therapy, rhTSH decreases goiter volume 35 to 56% more than non-stimulated radioiodine therapy (316 [EL 4], 325 [EL 1], 326 [EL 3]). It also improves respiratory function (315 [EL 4-review], 316 [EL 4]). However, it is unclear whether its use increases patient satisfaction (325 [EL 1]). The goiter-decreasing effect increases with greater thyroid size, in contrast to the effect without rhTSH prestimulation. Thus, it is possible to reduce radioiodine activity in correspondence with the increase in radioiodine uptake obtained with rhTSH stimulation while achieving the same decrease in goiter size. This decreases radioiodine activity and thereby decreases the theoretical risk of extrathyroidal malignancy. The induction of transient dose-dependent hyperthyroidism is the main adverse effect, starting 4 to 8 hours after rhTSH injection and peaking after 24 to 48 hours, with normalization within 3 weeks. With rhTSH doses  $\leq 0.1$  mg, thyroid hormone levels are maintained within the reference range in most patients (321 [EL 2]), with no alterations in structural or functional parameters of the heart (327 [EL 3]). Acute (within 24-48 hours) dose-related swelling of the normal thyroid has been demonstrated with an increase in mean thyroid volume of 35% with 0.9 mg rhTSH, 24% with 0.3 mg rhTSH, and 10% with 0.1 mg rhTSH (319 [EL 2], 320 [EL 2]). Therefore, the optimal rhTSH dose seems to be  $\leq 0.1$  mg (328 [EL 1], 329 [EL 3]).

The main long-term complication of rhTSH use is an increased rate of hypothyroidism. Three randomized studies (316 [EL 4], 324 [EL 4-review], 326 [EL 3]) showed increases of up to five-fold in the hypothyroidism rate in the rhTSH groups (21%, 61%, and 65%, respectively) compared with the rates in corresponding control groups (7%, 11%, and 21%, respectively). As seen with conventional radioiodine therapy, the incidence of hypothyroidism is positively related to goiter volume reduction. It is unclear whether rhTSH-stimulated radioiodine therapy increases the risk of thyroidal and extrathyroidal malignancy. Long-term efficacy is retained (323 [EL 1]), and modified release of rhTSH (slow release rhTSH) does not seem to have advantages over rhTSH (330 [EL 1], 331 [EL 1], 332 [EL 1]).

### 7.3. Indeterminate Lesions

#### 7.3.1. Management

In this category, no clear-cut morphologic criteria are available to distinguish benign from malignant lesions (141 [EL 4], 150 [EL 4], 151 [EL 4-consensus], 152 [EL 4]). Clinical criteria, such as personal or family history of thyroid cancer and lesion size, are associated with a moderate increase in the risk of malignancy, while US features and elastography provide relevant adjunct information for assessing the risk of thyroid carcinoma in cases with indeterminate cytologic characteristics (140 [EL 2], 333 [EL 2]). Hence, management of indeterminate thyroid nodules should not only be based on their cytologic subclassification, but also on clinical data, US and elastography findings, and, possibly, mutational analyses. Interdisciplinary consultation is recommended in the management of these cases, and the diagnostic and therapeutic options should be discussed with the patient (61 [EL 4]).

#### 7.3.2. Subclasses of indeterminate cytologic findings

##### 7.3.2.1. Management of low-risk indeterminate nodules (AUS/FLUS, Thy 3a, or TIR 3A cytologic category)

The expected risk of malignancy is 5 to 15% for this category of thyroid lesions (141 [EL 4]). With regard to AUS/FLUS lesions, the incidence of malignancy is highly variable depending upon the institution. Thus, it is important to know the institutional rate of malignancy of this diagnostic category to guide conservative or surgical management. A repeat FNA may provide a definitive cytologic diagnosis of benign or malignant in nearly 50% of cases with indeterminate cytologic findings (333 [EL 2], 334 [EL 2]). In a study of 150 patients with indeterminate cytologic characteristics, a second FNA was nondiagnostic in 2 (1.3%) nodules and benign in 54 (36%) nodules, AUS/FLUS diagnosis persisted in 73 (48.6%), and cytologic findings were suspicious in 11 (7.3%) and malignant in 10 (6.6%). These data were confirmed in a study of 422 patients with indeterminate cytologic characteristics (159 [EL 3]). A repeat FNA provided a result of benign in 178, confirmed indeterminate features in 161, and showed suspicious or malignant cytologic features in the remaining

patients. However, a study of 331 cases of AUS/FLUS cytologic findings did not show a statistically significant difference in malignancy rate among patients who went directly to surgery after a single AUS diagnosis, patients having 2 successive AUS FNA diagnoses, or patients with a benign aspirate after their first AUS cytologic analysis (163 [EL 3]). Thus, a benign cytologic determination that follows a previous AUS/FLUS diagnosis provides information that should be cautiously evaluated because it carries a lower but nonnegligible risk of malignancy.

CNB has been proposed in the management of the AUS/FLUS subcategory because the architectural findings and comparison with the surrounding normal thyroid tissue may provide further information (335 [EL 2]). However, the role of CNB in indeterminate lesions requires confirmation.

Immunocytochemical analyses may improve cytologic diagnosis accuracy, but they do not have a consistent predictive value for malignancy. Their use is still costly and should be restricted to specialized centers (196 [EL 3], 201 [EL 2]).

The determination of somatic mutations in indeterminate nodules has been proposed as a tool for differentiating benign from malignant nodules (216 [EL 4]). Molecular analyses of different oncogenes do not provide a certain distinction between follicular adenomas and follicular cancers because of the lack of specific gene alterations. However, the determination of a panel of mutations (210 [EL 2], 211 [EL 2]) may decrease the risk of overlooking malignancy to about 5% in mutation-negative patients (213 [EL 2], 216 [EL 4]).

The study of several GECs (214 [EL 2], 215 [EL 2]) was reported to have a high NPV in indeterminate nodules. However, recent studies of Afirma GEC demonstrate a lower-than-expected rate of benign findings in negative FN/HCN and a lower-than-anticipated malignancy rate within GEC-suspicious nodules. These data suggest that both the NPV and PPV of the Afirma GEC may vary significantly from what was previously reported (336 [EL 2]).

Close follow-up is suggested as the preferential option for most AUS/FLUS nodules (150 [EL 4], 151 [EL 4-consensus], 152 [EL 4]). Conservative management is supported by favorable clinical criteria based on personal and family history, small lesion size, and if there is a relatively low observed incidence of malignancy for these categories (154 [EL 2]). However, the most important factor in decision-making is represented by low-risk US and elastography features (140 [EL 2]). A repeat FNA for cytologic examination is recommended but may not offer conclusive additional information. CNB may be considered to provide microhistologic information, but its role in indeterminate lesions is unsettled. In the near future, a more robust rule-in approach may be provided by next-generation sequencing assays (140b [EL 2]).

Patients with suspicious clinical or US findings should preferentially be treated with lobectomy and isthmectomy (61 [EL 4],337 [EL 4-guidelines]). Total thyroidectomy may be considered depending on the clinical setting, coexistence of contralateral nodules, and patient preference (61 [EL 4]).

7.3.2.2 Management of high-risk indeterminate nodules (FN/SFN, Thy 3f, or TIR 3B cytologic categories)

In this category, the expected risk of malignancy is higher, at about 15 to 30%. Repeat FNA of nodules classified as follicular neoplasm is not generally recommended because it does not provide additional information for management (150 [EL 4],151 [EL 4-consensus],152 [EL 4],334 [EL 2]). FNA may be repeated only in cases with the diagnosis of “atypical cells” to assess a possible follicular variant of PTC (151 [EL 4-consensus]). CNB may be considered, but its use is not recommended in the management of this subcategory (151 [EL 4-consensus],152 [EL 4]).

Surgical excision of the lesion with histologic examination should be performed in most cases (61 [EL 4],337 [EL 4-guidelines]). In patients with favorable clinical and US features or immunohistochemical markers, a multidisciplinary team may consider close clinical follow-up without immediate diagnostic surgery (61 [EL 4],152 [EL 4]). Molecular testing may be considered, if available, to reinforce the choice of a conservative strategy in these patients. Yet, molecular analyses do not provide a conclusive diagnosis. In a recent study of 31 indeterminate nodules submitted to surgery, GEC showed a 15% PPV and 75% NPV (336 [EL 2]). Testing for a panel of mutations may provide a diagnosis of malignancy in 20 to 40% of FN cases, but nodules that are negative for mutation still carry a substantial risk of malignancy. In evaluating the indication and timing for surgery, it should be considered that patients with indeterminate cytologic and histologic characteristics of thyroid cancer generally have an overall good prognosis (140 [EL 2]).

Patients with follicular thyroid lesions are preferentially treated with diagnostic thyroid lobectomy and isthmectomy (61 [EL 4],337 [EL 4-guidelines]). Total thyroidectomy may be performed on the basis of the clinical setting, coexistence of multiple thyroid nodules, and patient preference. Frozen sections are usually not useful (152 [EL 4]).

#### 7.4. Management of FNA-Suspicious Nodules

This category includes samples characterized by cytologic features that are suggestive of but do not fulfill the criteria for a definite diagnosis of malignancy (141 [EL 4]). It also includes samples with inadequate cellularity but cellular features strongly suggestive of malignancy (150 [EL 4],151 [EL 4-guidelines],152 [EL 4]). The rate of histologically confirmed malignancy in these cases is about 60 to 75% (159 [EL 3],160 [EL 2]), with papillary carcinoma being the most frequent histologic type.

Surgery is generally recommended (151 [EL 4-guidelines],152 [EL 4]). Intraoperative histologic examination may be used because frozen sections may help guide surgical decision-making (338 [EL 3],339 [EL 4-guidelines]). FNA may be repeated, depending on the opinion of the clinician or pathologist, when further material is needed for ancillary studies such as immunocytochemistry or flow cytometry (151 [EL 4-guidelines],152 [EL 4]).

#### 7.5. Nodules Found Malignant by FNA

This class includes cases with a definitive cytologic diagnosis of malignant neoplasm (papillary, medullary, poorly differentiated, and anaplastic carcinoma; lymphoma; other nonepithelial malignancies and metastases) (141 [EL 4]). This category, depending on the series, accounts from 2.7 to 5% of the cytologic diagnoses, and the risk of malignancy is >95% (159 [EL 3],160 [EL 2]).

Before surgery, thyroid US and cytologic results should be reviewed with the patient and the family, and treatment options should be discussed (61 [EL 4]). Surgical excision should be recommended and its potential complications discussed. Consultation with a surgeon experienced in endocrine surgical procedures should be obtained as soon as possible. The surgical approach and its extent should be planned according to the clinical setting and imaging findings (61 [EL 4],234 [EL 4-guidelines],337 [EL 4-guidelines],340 [EL 4-consensus]).

Preoperatively, in addition to evaluation by an anesthesiologist, patients with documented thyroid cancer should undergo US examination of the neck, FNA of any concomitant suspicious nodule or lymph node, and vocal cord assessment with fiberoptic laryngoscopy (61 [EL 4],337 [EL 4-guidelines],341 [EL 4-guidelines]). In the case of suspicious US features, the malignant nature of a cervical mass should be clarified with measurement of Tg or calcitonin in the FNA needle washout (119 [EL 2],120 [EL 2],342 [EL 4]).

Surgery is recommended if cytologic results are compatible with a differentiated thyroid carcinoma (234 [EL 4-guidelines],339 [EL 4-guidelines],340 [EL 4-consensus]). The choice of total thyroidectomy, with or without lymphadenectomy, or of a more conservative approach is based on preoperative staging and the clinical setting (61 [EL 4]). Thus, in some elderly patients with incidentally discovered PTMC who are at high surgical risk and have no evidence of extrathyroid spreading, a close clinical and US follow-up may be acceptable (15 [EL 3],343 [EL 4-review]). Lesions with a diagnosis of anaplastic carcinoma or lymphoma and metastatic tumors should be addressed by additional diagnostic techniques and possibly by therapeutic procedures other than thyroidectomy (61 [EL 4],152 [EL 4],337 [EL 4-guidelines]).

CT, MRI, and <sup>18</sup>F PET may be relevant in selected cases of aggressive tumors if needed to assess nodal or airway involvement, substernal extension, or distant metastases (61 [EL 4],344 [EL 4]).

Treatment and management of thyroid cancer are not covered by this guideline.

### Recommendations: Management and Therapy

#### 7.1. Nodules Nondiagnostic by FNA

- If initial FNA is nondiagnostic and the nodule is solid on US, we recommend repeating the procedure with US guidance [BEL 2, GRADE A].
- When cytologic results by FNA are repeatedly inadequate in solid nodules, consider performing an US-guided CNB [BEL 3, GRADE C].
- Consider surgery for persistently nondiagnostic hypoechoic solid nodules. Follow-up may be considered in a minority of solid nodules with clearly favorable clinical and US features [BEL 3, GRADE C].
- Consider clinical and US follow-up for persistently nondiagnostic cystic or predominantly cystic nodules without suspicious clinical or US features [BEL 3, GRADE C].

#### 7.2. Nodules Benign by FNA

##### 7.2.1. Follow-up

- Perform clinical follow-up of FNA-benign nodules unless symptomatic [BEL 2, GRADE A].
- Consider a repeat clinical and US examination plus TSH measurement in approximately 12 months, in accordance with the clinical setting [BEL 3, GRADE C].
- If nodules are unchanged at the first US control, repeat US after 24 months [BEL 3, GRADE C].
- In nodules with benign cytology but suspicious clinical or US features, a repeat FNA is recommended [BEL 2, GRADE A].
- Repeat FNA is recommended in nodules with a >50% increase in volume or in those that become symptomatic [BEL 3, GRADE B].

##### 7.2.2. Medical treatment for benign nodules

- $LT_4$  suppressive therapy is not recommended [BEL 1, GRADE A].
- In geographic areas with mild iodine deficiency, iodine supplementation, and/or TSH nonsuppressive  $LT_4$  treatment may be considered for young patients with a small nodular goiter and high-normal TSH levels [BEL 2, GRADE B].
- Nonsuppressive  $LT_4$  treatment is recommended for young patients with subclinical hypothyroidism due to autoimmune thyroiditis [BEL 2, GRADE A].
- $LT_4$  therapy is not recommended for preventing recurrence after lobectomy when serum TSH remains in reference range [BEL 2, GRADE A].

##### 7.2.3. Surgical indications for benign nodules

- Consider surgery when local pressure symptoms are present or are clearly associated with the nodule(s) or in case of appearance of suspicious US features, despite benign FNA findings [BEL 2, GRADE B].
- Optimal surgical excision is lobectomy plus isthmectomy for benign uninodular goiter and total thyroidectomy for MNG [BEL 2, GRADE A].

##### 7.2.4. Percutaneous ethanol injection for benign nodules

- PEI is a safe and effective outpatient therapy for benign thyroid cysts or complex nodules with a large fluid component [BEL 1, GRADE A].
- Carefully sample the solid component of complex lesions and confirm that they are benign before PEI [BEL 3, GRADE B].
- PEI is recommended as the first-line treatment for relapsing benign cystic lesions [BEL 1, GRADE A].
- PEI is not recommended for solid nodules, whether hyperfunctioning or not, or for MNGs. This procedure may be considered for hot nodules having compressive symptoms only when other treatment modalities are not accessible [BEL 2, GRADE A].

##### 7.2.5. Image-guided thermal ablation for benign nodules

- Consider laser or radiofrequency ablation for the treatment of solid or complex thyroid nodules that progressively enlarge, are symptomatic, or cause cosmetic concern [BEL 2, GRADE C].
- Repeat FNA for cytologic confirmation before thermal ablation treatment [BEL 3, GRADE B].
- Discuss alternative therapy options and their efficacy, limitations, and adverse effects with the patient [BEL 3, GRADE B].

##### 7.2.6. Radioiodine therapy

###### 7.2.6.1. When and how to perform radioiodine therapy

- Consider radioiodine therapy for hyperfunctioning and/or symptomatic goiters, especially for patients with previous thyroid surgery or at surgical risk and in those who decline surgery [BEL 2, GRADE A].
- Perform FNA before radioiodine therapy on coexistent cold nodules per the recommendations for nontoxic MNG [BEL 3, GRADE B].
- Avoid the use of iodine contrast agents or iodinated drugs before radioiodine administration [BEL 2, GRADE A].

- If possible, withdraw antithyroid drugs 4 to 7 days before treatment and consider resumption 1 week after radioiodine therapy [BEL 2, GRADE B].

#### 7.2.6.2. Contraindications

- Radioiodine is contraindicated in pregnant or breastfeeding subjects [BEL 2, GRADE A].
- In subjects of childbearing potential, perform a pregnancy test before administering radioiodine [BEL 2, GRADE A].

#### 7.2.6.3. Follow-up after radioiodine therapy

- Regular thyroid function monitoring is recommended [BEL 2, GRADE A].
- Consider repeating treatment after 3 to 6 months in case of persistent or recurrent hyperthyroidism or inadequate size reduction [BEL 3, GRADE B].

### 7.3. Indeterminate Lesions

#### 7.3.1. Management

- Base the management of indeterminate thyroid nodules on the combination of cytologic subclassification, clinical data, and US features [BEL 2, GRADE A].
- Consider elastography, when available, for additional information [BEL 2, GRADE B].
- Consider the available technical resources and patient preferences [BEL 4, GRADE D].

#### 7.3.2. Subclasses of indeterminate cytologic findings

- On the basis of morphologic alterations and background component, distinguish 2 cytologic subclasses at different expected risks of malignancy according to the BSRTC classification or to comparable cytologic classification systems (see Table 2) [BEL 2, GRADE A].

#### 7.3.2.1. Management of low-risk indeterminate lesions (AUS/FLUS, Thy 3a, or TIR 3A category nodules)

- Consider conservative management in the case of favorable clinical criteria, such as personal or family history, lesion size, and low-risk US and elastography features [BEL 3, GRADE B].
- Repeat FNA for further cytologic assessment, and review the samples with an experienced cytopathologist [BEL 3, GRADE B].
- CNB may be considered to provide microhistologic information, but routine use is not currently recommended because its role in indeterminate lesions is still unsettled [BEL 4, GRADE C].
- We do not recommend either in favor of or against the routine use of molecular

markers in this category [BEL 3, GRADE D].

#### 7.3.2.2. Management of high-risk indeterminate lesions (FN/SFN, Thy 3f, or TIR 3B category nodules)

- Surgery is recommended for most thyroid lesions in this category [BEL 2, GRADE A].
- Thyroid lobectomy plus isthmectomy is recommended; total thyroidectomy may be performed, depending on the clinical situation, coexistence of bilateral thyroid nodules, or patient preference [BEL 2, GRADE A].
- Frozen sections are usually not useful in this group [BEL 3, GRADE D].
- Consider close clinical follow-up in a minority of cases with favorable clinical and US features after multidisciplinary consultation and discussion of treatment options with the patient [BEL 4, GRADE C].

#### 7.4. Management of FNA-Suspicious Nodules

- Surgery is recommended [BEL 1, GRADE A].
- Repeat the FNA with poor inadequate cellularity or in those that need additional techniques for a better characterization [BEL 3, GRADE B].
- Intraoperative frozen sections may be considered [BEL 3, GRADE D].

### 7.5. Nodules Malignant by FNA

#### 7.5.1. Management

- In the case of differentiated thyroid carcinoma, surgical treatment is always recommended [BEL 1, GRADE A].
- For anaplastic carcinoma, metastatic lesions, and thyroid lymphoma, further diagnostic work-up is recommended before total thyroidectomy or therapeutic procedures other than surgery, if appropriate [BEL 2, GRADE A]. When malignancy is suspected to be a metastasis to the thyroid, a search for the primary tumor site should be undertaken before thyroid surgery.

#### 7.5.2. Preoperative evaluation

- Review US and cytologic results with the patient; discuss treatment options, and obtain consultation with a surgeon experienced in endocrine surgery [BEL 2, GRADE A].
- US examination of the neck, FNA biopsy of any concomitant suspicious nodule or lymph node, and vocal cord assessment with laryngoscopy are recommended before surgery [BEL 2, GRADE A].

- In the case of suspicious US features, confirm the metastatic nature of a lymph node with measurement of Tg or calcitonin in the wash-out of the FNA needle [BEL 2, GRADE A].
- Consider the use of MRI, CT, and/or <sup>18</sup>F-DG PET/CT in selected cases with aggressive features for a more accurate preoperative staging [BEL 2, GRADE B].

## 8. Thyroid Nodules During Pregnancy

### 8.1. Clinical Approach

Most cases of thyroid nodules during pregnancy occur in patients with pre-existing nodules. Occasionally, however, a thyroid nodule is detected for the first time during pregnancy. This should be managed in the same way as in nonpregnant patients, except for avoiding the use of radioactive agents for diagnostic and therapeutic purposes (61 [EL 4],296 [EL 4-guidelines],298 [EL 4-guidelines],345 [EL 4]). If thyroid nodule diagnosis during pregnancy necessitates FNA, the procedure is not contraindicated regardless of the gestational age of the fetus (61 [EL 4],345 [EL 4]).

Sharing findings among the endocrinologist, obstetrician, thyroid surgeon, pathologist, and anesthesiologist is recommended, as well as taking patient preference into consideration (61 [EL 4],234 [EL 4-guidelines],345 [EL 4]).

In one series, thyroid nodules were diagnosed in 34 of 221 pregnant patients who were monitored for 3 months after delivery (346 [EL 2]). The volume of the single or dominant thyroid nodule increased from a mean of 60 mm<sup>3</sup> at the beginning of pregnancy to 65 mm<sup>3</sup> at the third trimester and 103 mm<sup>3</sup> at 6 weeks after delivery. At 3 months' postpartum, the volume was still greater than in early pregnancy (73 mm<sup>3</sup>). New thyroid nodules developed in 11.3% of females during pregnancy; this circumstance led to an increase in the prevalence of nodular thyroid disease, from 15.3% at baseline to 24.4% at 3 months after delivery. None of the new thyroid nodules discovered on US were palpable. These data indicate that pregnancy is associated with an increase in the size of pre-existing nodules and, in a few cases, with the appearance of new thyroid nodules, possibly because of the negative iodine balance that frequently occurs during pregnancy (347 [EL 4]).

Although pregnancy is a risk factor for progression of nodular thyroid disease, no available evidence indicates that LT<sub>4</sub> is effective in decreasing the size or arresting thyroid nodule growth during pregnancy (341 [EL 4-guidelines]). TSH-suppressive therapy with LT<sub>4</sub> is not recommended during pregnancy; however, iodine supplementation should be carefully considered in borderline iodine-deficient areas (345 [EL 4-guidelines]).

Suspicious cytologic findings pose only minor problems during pregnancy. Although pregnancy has been

reported to cause inappropriate diagnosis of follicular neoplasms because of a physiologic increase in follicular epithelium, the malignancy rate of follicular neoplasms in pregnant patients is similar to that in nonpregnant subjects, at about 14% (348 [EL 3]). Therefore, the diagnosis and management of indeterminate nodules should be similar to that of nonpregnant patients. In the absence of severe local symptoms or worrying findings, postponing surgical treatment to the postpartum period is suggested (61 [EL 4],234 [EL 4-guidelines]).

### 8.2. Management of FNA-Malignant Nodules

Thyroid cancer is rarely diagnosed during pregnancy. If cancer is diagnosed during the first or second trimester, the patient may undergo surgical treatment during the second trimester, when risks are minimal (61 [EL 4],234 [EL 4-guidelines],337 [EL 4-guidelines]). Most, if not all, series have demonstrated a negligible (349 [EL 3],350 [EL 2],351 [EL 4]) or moderate (352 [EL 3]) influence of delayed surgery on the prognosis of pregnant subjects with differentiated thyroid carcinoma. Thus, subjects without cytologic, clinical, or US evidence of aggressive thyroid cancer should be reassured that surgical treatment performed soon after delivery is unlikely to adversely affect their prognosis. If the cytologic diagnosis is made during the third trimester, the surgical procedure may most often be postponed until the immediate postpartum period (61 [EL 4]). Close clinical and US monitoring and interdisciplinary consultation are recommended.

## Recommendations: Thyroid Nodules during Pregnancy

### 8.1. Clinical Approach

- Manage thyroid nodules in pregnant patients in the same way as in nonpregnant patients [BEL 2, GRADE A].
- When suspicious clinical or US findings are present, we recommend FNA since cytologic diagnostic criteria are not substantially influenced by pregnancy [BEL 2, GRADE A].
- Use of radioactive agents for diagnostic and therapeutic purposes is contraindicated [BEL 2, GRADE A].
- In the case of suppressed TSH levels during the second half of pregnancy, postpone radio-nuclide thyroid scan until after delivery and cessation of breastfeeding [BEL 2, GRADE A].
- During pregnancy, TSH-suppressive LT<sub>4</sub> therapy for thyroid nodules or goiter is not recommended [BEL 3, GRADE B]. Iodine supplementation should be used in pregnant subjects living in iodine-deficient regions [BEL 2, GRADE A].
- For thyroid nodules that grow substantially or become symptomatic during pregnancy,

follow-up with US examination and FNA (if appropriate) is recommended [BEL 2, GRADE A].

- If FNA shows indeterminate cytologic findings, we recommend US monitoring and postponing surgery until after delivery [BEL 3, GRADE B].

#### 8.2. Management of FNA-Malignant Nodules

- When a thyroid malignancy is diagnosed during the first or second trimester, thyroidectomy may be performed during the second trimester [BEL 3, GRADE B].
- For subjects with clinical or US evidence of extracapsular growth or lymph node metastases, consider surgical treatment during the second trimester of pregnancy [BEL 3, GRADE B].
- Women without evidence of aggressive thyroid cancer should be reassured that surgical treatment performed soon after delivery is unlikely to adversely affect prognosis. Close clinical and US monitoring is recommended [BEL 3, GRADE B].
- When a thyroid malignancy is diagnosed during the third trimester, surgical treatment can be deferred until the immediate postpartum period [BEL 3, GRADE B].
- For females with suspicious or malignant thyroid nodules in whom surgery is postponed until after delivery, we suggest maintenance of TSH at low-normal levels [BEL 3, GRADE B].

### 9. Management of Thyroid Nodules in Children

Although no epidemiologic studies of thyroid nodules in children are available, small cohort studies report prevalence rates of thyroid nodules in prepubertal children of up to 1.8% (353 [EL 4],354 [EL 4-review]). A few small, retrospective cohort studies report higher malignancy rates for thyroid nodules in children than in adults, with a mean malignancy rate of 26% for operated thyroid nodules in children (355 [EL 3]) and 9 to 18% malignant and suspicious results for children undergoing FNA (355 [EL 3],356 [EL 3],357 [EL 3]). The lower prevalence of thyroid nodules in children, associated with higher malignancy rates than in adults, suggests applying a lower threshold for thyroid nodule surgery in pediatric patients.

Diagnostic and therapeutic practice patterns vary considerably for thyroid nodules in children (358 [EL 4]). FNA sensitivity and specificity in children are 86 to 100% and 65 to 90%, respectively (24 [EL 3],356 [EL 3]), and thyroid US criteria for malignancy seem to have a low predictive value in children (269 [EL 3],359 [EL 2]). In a recent study of 89 patients younger than 18 years who had thyroid nodules >8 mm and were submitted to FNA, 27% were diagnosed with differentiated thyroid carcinoma, mostly of the papillary type (360 [EL 2]). Features associated with

malignancy were large size, presence of suspicious lymph nodes, and suspicious US findings.

Despite a high prevalence of positive lymph nodes and lung metastases at presentation, the prognosis of PTC in children is generally good (361 [EL 4-review]). Young age, however, is a main determinant of recurrence in children (362 [EL 3]). Whereas thyroid carcinomas in children are mostly papillary, several case reports describe follicular thyroid carcinomas in patients with congenital hypothyroidism (347 [EL 4]) who also have an increased incidence of thyroid nodules. Moreover, hot nodules in children carry a greater risk of malignancy compared to adults (363 [EL 3]).

#### Recommendations: Management of Thyroid Nodules in Children

- Evaluation and management of nodular disease in children is similar to those in adults [BEL 3, GRADE 2].
- Because of a higher prevalence of malignancy in children, the threshold for considering surgical therapy for cold, as well as hot, nodules should be low [BEL 3, GRADE C].

### ACKNOWLEDGMENT

AACE/AME Task Force on Thyroid Nodule Committee Members include the listed authors and Sofia Tseleni Balafouta, MD; Zubair Baloch, MD; Anna Crescenzi, MD; Henning Dralle, MD; Andrea Frasoldati, MD; Roland Gärtner, MD; Rinaldo Guglielmi, MD; Jeffrey I. Mechanick, MD, FACP, FACN, FACE; Christoph Reiners, MD; Istvan Szabolcs, MD, PhD, DSc; Martha A. Zeiger, MD, FACS; and Michele Zini, MD.

### DISCLOSURE

#### AACE/ACE/AME Task Force on Thyroid Nodules

*Dr. Zubair Baloch* reports that he has received consultant honorarium from Veracyte, Inc.

*Dr. Anna Crescenzi* reports that she does not have any relevant financial relationships with any commercial interests.

*Dr. Henning Dralle* reports that he does not have any relevant financial relationships with any commercial interests.

*Dr. Andrea Frasoldati* reports that he does not have any relevant financial relationships with any commercial interests.

*Dr. Roland Gärtner* reports that he does not have any relevant financial relationships with any commercial interests.

*Dr. Rinaldo Guglielmi* reports that he does not have any relevant financial relationships with any commercial interests.

**Dr. Jeffrey I. Mechanick** reports that he does not have any relevant financial relationships with any commercial interests.

**Dr. Christoph Reiners** reports that he does not have any relevant financial relationships with any commercial interests.

**Dr. Istvan Szabolcs** reports that he has received speaker honorarium from Berlin-Chemie AG, Genzyme Corporation, and Merck AG.

**Dr. Martha A. Zeiger** reports that she does not have any relevant financial relationships with any commercial interests.

**Dr. Michele Zini** reports that she does not have any relevant financial relationships with any commercial interests.

#### Primary Authors

**Dr. Hossein Gharib** reports that he does not have any relevant financial relationships with any commercial interests.

**Dr. Enrico Papini** reports that he does not have any relevant financial relationships with any commercial interests.

**Dr. Ralf Paschke** reports that he has received speaker honoraria from Merck & Co, Inc, and Sanofi-Aventis U.S., LLC.

**Dr. Daniel S. Duick** reports that he has received speaker honorarium from Genzyme Corporation.

**Dr. Roberto Valcavi** reports that he does not have any relevant financial relationships with any commercial interests.

**Dr. Laszlo Hegedüs** reports that he has received consultant honoraria and research grant support from Novo Nordisk A/S and Genzyme Corporation and consultant and speaker honoraria from Theraclion.

**Dr. Paolo Vitti** reports that he does not have any relevant financial relationships with any commercial interests.

**Dr. Jeffrey R. Garber** reports no disclosures.

**Dr. Mack Harrell** reports no disclosures.

#### REFERENCES

*Note:* All reference sources are followed by an evidence level (EL) rating of 1, 2, 3, or 4. The strongest evidence levels [EL 1 and EL 2] appear in red for easier recognition.

1. **Gharib H, Papini E.** Thyroid nodules: clinical importance, assessment, and treatment. *Endocrinol Metab Clin North Am.* 2007;36:707-735, vi. [EL 4-review]
2. **Hegedüs L.** Clinical practice. The thyroid nodule. *N Engl J Med.* 2004;351:1764-1771. [EL 4-review]
3. **Tunbridge WM, Evered DC, Hall R, et al.** The spectrum of thyroid disease in a community: the Wickham survey. *Clin Endocrinol (Oxf).* 1977;7:481-493. [EL 2]
4. **Reiners C, Wegscheider K, Schicha H, et al.** Prevalence of thyroid disorders in the working population of Germany: ultrasonography screening in 96,278 unselected employees. *Thyroid.* 2004;14:926-932. [EL 2]
5. **Dean DS, Gharib H.** Epidemiology of thyroid nodules. *Best Pract Res Clin Endocrinol Metab.* 2008;22:901-911. [EL 4]
6. **Guth S, Theune U, Aberle J, Galach A, Bamberger CM.** Very high prevalence of thyroid nodules detected by high frequency (13 MHz) ultrasound examination. *Eur J Clin Invest.* 2009;39:699-706. [EL 2]
7. **Mortensen JD, Woolner LB, Bennett WA.** Gross and microscopic findings in clinically normal thyroid glands. *J Clin Endocrinol Metab.* 1955;15:1270-1280. [EL 3]
8. **Tan GH, Gharib H.** Thyroid incidentalomas: management approaches to nonpalpable nodules discovered incidentally on thyroid imaging. *Ann Intern Med.* 1997;126:226-231. [EL 4]
9. **Steele SR, Martin MJ, Mullenix PS, Azarow KS, Andersen CA.** The significance of incidental thyroid abnormalities identified during carotid duplex ultrasonography. *Arch Surg.* 2005;140:981-985. [EL 2]
10. **Kang BJ, O JH, Baik JH, Jung SL, Park YH, Chung SK.** Incidental thyroid uptake on F-18 FDG PET/CT: correlation with ultrasonography and pathology. *Ann Nucl Med.* 2009;23:729-737. [EL 2]
11. **Jin J, McHenry CR.** Thyroid incidentaloma. *Best Pract Res Clin Endocrinol Metab.* 2012;26:83-96. [EL 4]
12. **Leenhardt L, Grosclaude P, Cherie-Challine L; Thyroid Cancer Committee.** Increased incidence of thyroid carcinoma in France: a true epidemic or thyroid nodule management effects? Report from the French Thyroid Cancer Committee. *Thyroid.* 2004;14:1056-1060. [EL 4]
13. **Davies L, Welch HG.** Increasing incidence of thyroid cancer in the United States, 1973-2002. *JAMA.* 2006;295:2164-2167. [EL 2]
14. **Zevallos JP, Hartman CM, Kramer JR, Sturgis EM, Chiao EY.** Increased thyroid cancer incidence corresponds to increased use of thyroid ultrasound and fine-needle aspiration: a study of the Veterans Affairs health care system. *Cancer.* 2015;121:741-746. [EL 3]
15. **Ito Y, Uruno T, Nakano K, et al.** An observation trial without surgical treatment in patients with papillary microcarcinoma of the thyroid. *Thyroid.* 2003;13:381-387. [EL 3]
16. **Cronan JJ.** Thyroid nodules: is it time to turn off the US machines? *Radiology.* 2008;247:602-604. [EL 4]
17. **Howlett DC, Speirs A.** The thyroid incidentaloma: ignore or investigate? *J Ultrasound Med.* 2007;26:1367-1371. [EL 4]
18. **Rosenbaum MA, McHenry CR.** Contemporary management of papillary carcinoma of the thyroid gland. *Expert Rev Anticancer Ther.* 2009;9:317-329. [EL 4-review]
19. **DeLellis RA, Lloyd RV, Heitz PU, Eng C, eds.** *World Health Organization Classification of Tumours. Pathology and Genetics of Tumours of Endocrine Organs.* Lyon, France: IARC Press, 2004. [EL 4-review]
20. **Aghini-Lombardi F, Antonangeli L, Martino E, et al.** The spectrum of thyroid disorders in an iodine-deficient community: the Pescopagano survey. *J Clin Endocrinol Metab.* 1999;84:561-566. [EL 2]
21. **Puñales MK, da Rocha AP, Meotti C, Gross JL, Maia AL.** Clinical and oncological features of children and young adults with multiple endocrine neoplasia type 2A. *Thyroid.* 2008;18:1261-1268. [EL 2]
22. **Campanella P, Ianni F, Rota CA, Corsello SM, Pontecorvi A.** Quantification of cancer risk of each clinical and ultrasonographic suspicious feature of thyroid nodules: a systematic review and meta-analysis. *Eur J Endocrinol.* 2014;170:R203-R211. [EL 2]



23. **Capezzone M, Marchisotta S, Cantara S, Busonero G, Brilli L, Pazaitou-Panayiotou K.** Familial non-medullary thyroid carcinoma displays the features of clinical anticipation suggestive of a distinct biological entity. *Endocr Relat Cancer.* 2008;15:1075-1081. [EL 3]
24. **Corrias A, Einaudi S, Chiorboli E, et al.** Accuracy of fine needle aspiration biopsy of thyroid nodules in detecting malignancy in childhood: comparison with conventional clinical, laboratory, and imaging approaches. *J Clin Endocrinol Metab.* 2001;86:4644-4648. [EL 3]
25. **Durante C, Costante G, Lucisano G, et al.** The natural history of benign thyroid nodules. *JAMA.* 2015;313:926-935. [EL 2]
26. **Negro R.** What happens in a 5-year follow-up of benign thyroid nodules. *J Thyroid Res.* 2014;2014:459791. [EL 3]
27. **Jarlov AE, Nygaard B, Hegedüs L, Hartling SG, Hansen JM.** Observer variation in the clinical and laboratory evaluation of patients with thyroid dysfunction and goiter. *Thyroid.* 1998;8:393-398. [EL 3]
28. **Gough J, Scott-Coombes D, Fausto Palazzo F.** Thyroid incidentaloma: an evidence-based assessment of management strategy. *World J Surg.* 2008;32:1264-1268. [EL 4]
29. **Papini E, Guglielmi R, Bianchini A, et al.** Risk of malignancy in nonpalpable thyroid nodules: predictive value of ultrasound and color-Doppler features. *J Clin Endocrinol Metab.* 2002;87:1941-1946. [EL 3]
30. **Christensen SB, Bondeson L, Ericsson UB, Lindholm K.** Prediction of malignancy in the solitary thyroid nodule by physical examination, thyroid scan, fine-needle biopsy and serum thyroglobulin: a prospective study of 100 surgically treated patients. *Acta Chir Scand.* 1984;150:433-439. [EL 3]
31. **Boelaert K, Horacek J, Holder RL, Watkinson JC, Sheppard MC, Franklyn JA.** Serum thyrotropin concentration as a novel predictor of malignancy in thyroid nodules investigated by fine-needle aspiration. *J Clin Endocrinol Metab.* 2006;91:4295-4301. [EL 3]
32. **Gerschpacher M, Gobl C, Anderwald C, Gessl A, Krebs M.** Thyrotropin serum concentrations in patients with papillary thyroid microcancers. *Thyroid.* 2010;20:389-392. [EL 3]
33. **Fiore E, Vitti P.** Serum TSH and risk of papillary thyroid cancer in nodular thyroid disease. *J Clin Endocrinol Metab.* 2012;97:1134-1145. [EL 2]
34. **Giovanella L, Fasolini F, Suriano S, Mazzucchelli L.** Hyperfunctioning solid/trabecular follicular carcinoma of the thyroid gland. *J Oncol.* 2010;2010. pii: 635984. [EL 3]
35. **Ashcraft MW, Van Herle AJ.** Management of thyroid nodules. II: Scanning techniques, thyroid suppressive therapy, and fine needle aspiration. *Head Neck Surg.* 1981;3:297-322. [EL 4-review]
36. **Yano Y, Shibuya H, Kitagawa W, et al.** Recent outcome of Graves' disease patients with papillary thyroid cancer. *Eur J Endocrinol.* 2007;157:325-329. [EL 3]
37. **Shetty SK, Maher MM, Hahn PF, Halpern EF, Aquino SL.** Significance of incidental thyroid lesions detected on CT: correlation among CT, sonography, and pathology. *AJR Am J Roentgenol.* 2006;187:1349-1356. Erratum in: *AJR Am J Roentgenol.* 2007;188:8. [EL 3]
38. **Razek AA, Sadek AG, Kombar OR, Elmahdy TE, Nada N.** Role of apparent diffusion coefficient values in differentiation between malignant and benign solitary thyroid nodules. *AJNR Am J Neuroradiol.* 2008;29:563-568. [EL 3]
39. **Are C, Hsu JF, Schoder H, Shah JP, Larson SM, Shaha AR.** FDG-PET detected thyroid incidentalomas: need for further investigation? *Ann Surg Oncol.* 2007;14:239-247. [EL 3]
40. **Choi JY, Lee KS, Kim HJ, et al.** Focal thyroid lesions incidentally identified by integrated 18F-FDG PET/CT: clinical significance and improved characterization. *J Nucl Med.* 2006;47:609-615. [EL 3]
41. **Soelberg KK, Bonnema SJ, Brix TH, Hegedüs L.** Risk of malignancy in thyroid incidentalomas detected by 18F-fluorodeoxyglucose positron emission tomography: a systematic review. *Thyroid.* 2012;22:918-925. [EL 2]
42. **Hurtado-López LM, Arellano-Montaña S, Torres-Acosta EM, et al.** Combined use of fine-needle aspiration biopsy, MIBI scans and frozen section biopsy offers the best diagnostic accuracy in the assessment of the hypo-functioning solitary thyroid nodule. *Eur J Nucl Med Mol Imaging.* 2004;31:1273-1279. [EL 3]
43. **Baskin HJ.** Ultrasound of thyroid nodules. In: Baskin HJ, ed. *Thyroid Ultrasound and Ultrasound-Guided FNA Biopsy.* Boston, MA: Springer U.S.; 2000: 71-86. [EL 4-review]
44. **Solbiati L, Osti V, Cova L, Tonolini M.** Ultrasound of thyroid, parathyroid glands and neck lymph nodes. *Eur Radiol.* 2001;11:2411-2424. [EL 4-review]
45. **Ahuja A, Ying M.** Sonography of neck lymph nodes. Part II: abnormal lymph nodes. *Clin Radiol.* 2003;58:359-366. [EL 4-review]
46. **Frates MC, Benson CB, Doubilet PM, et al.** Prevalence and distribution of carcinoma in patients with solitary and multiple thyroid nodules on sonography. *J Clin Endocrinol Metab.* 2006;91:3411-3417. [EL 3]
47. **Mandel SJ.** Diagnostic use of ultrasonography in patients with nodular thyroid disease. *Endocr Pract.* 2004;10:246-252. [EL 4-review]
48. **Horvath E, Majlis S, Rossi R, et al.** An ultrasonogram reporting system for thyroid nodules stratifying cancer risk for clinical management. *J Clin Endocrinol Metab.* 2009;94:1748-1751. [EL 2]
49. **Moon WJ, Jung SL, Lee JH, et al.** Benign and malignant thyroid nodules: US differentiation multicenter retrospective study. *Radiology.* 2008;247:762-770. [EL 3]
50. **Kim EK, Park CS, Chung WY, et al.** New sonographic criteria for recommending fine-needle aspiration biopsy of nonpalpable solid nodules of the thyroid. *AJR Am J Roentgenol.* 2002;178:687-691. [EL 2]
51. **Cappelli C, Castellano M, Pirola I, et al.** Thyroid nodule shape suggests malignancy. *Eur J Endocrinol.* 2006;155:27-31. [EL 3]
52. **Kwak JY, Jung I, Baek JH, et al.** Image reporting and characterization system for ultrasound features of thyroid nodules: multicentric Korean retrospective study. *Korean J Radiol.* 2013;14:110-117. Erratum in: *Korean J Radiol.* 2013;14:389. [EL 2]
53. **Hagag P, Strauss S, Weiss M.** Role of ultrasound-guided fine-needle aspiration biopsy in evaluation of nonpalpable thyroid nodules. *Thyroid.* 1998;8:989-995. [EL 3]
54. **Verburg FA, Mader U, Luster M, Reinert C.** Primary tumour diameter as a risk factor for advanced disease features of differentiated thyroid carcinoma. *Clin Endocrinol (Oxf).* 2009;71:291-297. [EL 3]
55. **McHenry CR, Huh ES, Machezano RN.** Is nodule size an independent predictor of thyroid malignancy? Surgery. 2008;144:1062-1068; discussion 1068-1069. [EL 3]

56. **Papini E, Petrucci L, Guglielmi R, et al.** Long-term changes in nodular goiter: a 5-year prospective randomized trial of levothyroxine suppressive therapy for benign cold thyroid nodules. *J Clin Endocrinol Metab.* 1998;83:780-783. [EL 1]
57. **Kuma K, Matsuzuka F, Yokozawa T, Miyauchi A, Sugawara M.** Fate of untreated benign thyroid nodules: results of long-term follow-up. *World J Surg.* 1994;18:495-498; discussion 499. [EL 2]
58. **Alexander EK, Hurwitz S, Heering JP, et al.** Natural history of benign solid and cystic thyroid nodules. *Ann Intern Med.* 2003;138:315-318. [EL 3]
59. **Ito Y, Miyauchi A, Inoue H, et al.** An observational trial for papillary thyroid microcarcinoma in Japanese patients. *World J Surg.* 2010;34:28-35. [EL 2]
60. **Gharib H, Papini E, Paschke R, et al.** American Association of Clinical Endocrinologists, Associazione Medici Endocrinologi, and European Thyroid Association medical guidelines for clinical practice for the diagnosis and management of thyroid nodules. *J Endocrinol Invest.* 2010;33 5 Suppl:1-50. [EL 4]
61. **Perros P, Boelaert K, Colley S, et al.** Guidelines for the management of thyroid cancer. *Clin Endocrinol (Oxf).* 2014;81 Suppl 1:1-122. [EL 4]
62. **Frates MC, Benson CB, Charboneau JW, et al.** Management of thyroid nodules detected at US: Society of Radiologists in ultrasound consensus conference statement. *Radiology.* 2005;237:794-800. [EL 4]
63. **Brauer VF, Eder P, Miehle K, Wiesner TD, Hasenclever H, Paschke R.** Interobserver variation for ultrasound determination of thyroid nodule volumes. *Thyroid.* 2005;15:1169-1175. [EL 2]
64. **Gallo M, Pesenti M, Valcavi R.** Ultrasound thyroid nodule measurements: the "gold standard" and its limitations in clinical decision making. *Endocr Pract.* 2003;9:194-199. [EL 4-review]
65. **Schlogl S, Werner E, Lassmann M, et al.** The use of three-dimensional ultrasound for thyroid volumetry. *Thyroid.* 2001;11:569-574. [EL 3]
66. **Kollorz EK, Hahn DA, Linke R, Goecke TW, Hornegger J, Kuwert T.** Quantification of thyroid volume using 3-D ultrasound imaging. *IEEE Trans Med Imaging.* 2008;27:457-466. [EL 3]
67. **Kim EK, Park CS, Chung WY, et al.** New sonographic criteria for recommending fine-needle aspiration biopsy of nonpalpable solid nodules of the thyroid. *AJR Am J Roentgenol.* 2002;178:687-691. [EL 2]
68. **Wienke JR, Chong WK, Fielding JR, Zou KH, Mittelstaedt CA.** Sonographic features of benign thyroid nodules: interobserver reliability and overlap with malignancy. *J Ultrasound Med.* 2003;22:1027-1031. [EL 2]
69. **Choi SH, Kim EK, Kwak JY, Kim MJ, Son EJ.** Interobserver and intraobserver variations in ultrasound assessment of thyroid nodules. *Thyroid.* 2010;20:167-172. [EL 2]
70. **Lee MJ, Kim EK, Kwak JY, Kim MJ.** Partially cystic thyroid nodules on ultrasound: probability of malignancy and sonographic differentiation. *Thyroid.* 2009;19:341-346. [EL 3]
71. **Chan BK, Desser TS, McDougall IR, Weigel RJ, Jeffrey RB Jr.** Common and uncommon sonographic features of papillary thyroid carcinoma. *J Ultrasound Med.* 2003;22:1083-1090. [EL 2]
72. **Lee S, Shin JH, Han BK, Ko EY.** Medullary thyroid carcinoma: comparison with papillary thyroid carcinoma and application of current sonographic criteria. *AJR Am J Roentgenol.* 2010;194:1090-1094. [EL 3]
73. **Kim SH, Kim BS, Jung SL, et al.** Ultrasonographic findings of medullary thyroid carcinoma: a comparison with papillary thyroid carcinoma. *Korean J Radiol.* 2009;10:101-105. [EL 3]
74. **Reading CC, Charboneau JW, Hay ID, Sebo TJ.** Sonography of thyroid nodules: a "classic pattern" diagnostic approach. *Ultrasound Q.* 2005;21:157-165. [EL 4]
75. **Yuan WH, Chiou HJ, Chou YH, et al.** Gray-scale and color Doppler ultrasonographic manifestations of papillary thyroid carcinoma: analysis of 51 cases. *Clin Imaging.* 2006;30:394-401. [EL 3]
76. **Propper RA, Skolnick ML, Weinstein BJ, Dekker A.** The nonspecificity of the thyroid halo sign. *J Clin Ultrasound.* 1980;8:129-132. [EL 3]
77. **Moon WJ, Baek JH, Jung SL, et al.** Ultrasonography and the ultrasound-based management of thyroid nodules: consensus statement and recommendations. *Korean J Radiol.* 2011;12:1-14. [EL 4]
78. **Khoo ML, Asa SL, Witterick IJ, Freeman JL.** Thyroid calcification and its association with thyroid carcinoma. *Head Neck.* 2002;24:651-655. [EL 3]
79. **Taki S, Terahata S, Yamashita R, et al.** Thyroid calcifications: sonographic patterns and incidence of cancer. *Clin Imaging.* 2004;28:368-371. [EL 3]
80. **Chammas MC, de Araujo Filho VJ, Moysés RA, et al.** Predictive value for malignancy in the finding of microcalcifications on ultrasonography of thyroid nodules. *Head Neck.* 2008;30:1206-1210. [EL 2]
81. **Kim MJ, Kim EK, Park SI, et al.** US-guided fine-needle aspiration of thyroid nodules: indications, techniques, results. *Radiographics.* 2008;28:1869-1886; discussion 1887. [EL 4]
82. **Wang N, Xu Y, Ge C, Guo R, Guo K.** Association of sonographically detected calcification with thyroid carcinoma. *Head Neck.* 2006;28:1077-1083. [EL 3]
83. **Hong YJ, Son EJ, Kim EK, Kwak JY, Hong SW, Chang HS.** Positive predictive values of sonographic features of solid thyroid nodule. *Clin Imaging.* 2010;34:127-33. [EL 2]
84. **Wu CW, Dionigi G, Lee KW, et al.** Calcifications in thyroid nodules identified on preoperative computed tomography: patterns and clinical significance. *Surgery.* 2012;151:464-470. [EL 3]
85. **Guglielmi R, Pacella CM, Bianchini A, et al.** Percutaneous ethanol injection treatment in benign thyroid lesions: role and efficacy. *Thyroid.* 2004;14:125-131. [EL 2]
86. **Yoon DY, Lee JW, Chang SK, et al.** Peripheral calcification in thyroid nodules: ultrasonographic features and prediction of malignancy. *J Ultrasound Med.* 2007;26:1349-1355; quiz 1356-1357. [EL 2]
87. **Kim BM, Kim MJ, Kim EK, et al.** Sonographic differentiation of thyroid nodules with eggshell calcifications. *J Ultrasound Med.* 2008;27:1425-1430. [EL 2]
88. **Tamsel S, Demirpolat G, Erdogan M, et al.** Power Doppler US patterns of vascularity and spectral Doppler US parameters in predicting malignancy in thyroid nodules. *Clin Radiol.* 2007;62:245-251. [EL 2]
89. **Moon HJ, Kwak JY, Kim MJ, Son EJ, Kim EK.** Can vascularity at power Doppler US help predict thyroid malignancy? *Radiology.* 2010;255:260-269. [EL 2]
90. **Jun P, Chow LC, Jeffrey RB.** The sonographic features of papillary thyroid carcinomas: pictorial essay. *Ultrasound Q.* 2005;21:39-45. [EL 4]

91. **Yoon JH, Kim EK, Hong SW, Kwak JY, Kim MJ.** Sonographic features of the follicular variant of papillary thyroid carcinoma. *J Ultrasound Med.* 2008;27:1431-1437. [EL 2]
92. **Kim DS, Kim JH, Na DG, et al.** Sonographic features of follicular variant papillary thyroid carcinomas in comparison with conventional papillary thyroid carcinomas. *J Ultrasound Med.* 2009;28:1685-1692. [EL 2]
93. **Choi YJ, Shin JH, Kim JH, Jung SL, Son EJ, Oh YL.** Tall cell variant of papillary thyroid carcinoma: sonographic and clinical findings. *J Ultrasound Med.* 2011;30:853-858. [EL 2]
94. **Zhang Y, Xia D, Lin P, Gao L, Li G, Zhang W.** Sonographic findings of the diffuse sclerosing variant of papillary carcinoma of the thyroid. *J Ultrasound Med.* 2010;29:1223-1226. [EL 3]
95. **Lee JY, Shin JH, Han BK, et al.** Diffuse sclerosing variant of papillary carcinoma of the thyroid: imaging and cytologic findings. *Thyroid.* 2007;17:567-573. [EL 3]
96. **Kwak JY, Kim EK, Hong SW, et al.** Diffuse sclerosing variant of papillary carcinoma of the thyroid: ultrasound features with histopathological correlation. *Clin Radiol.* 2007;62:382-386. [EL 3]
97. **Jeh SK, Jung SL, Kim BS, Lee YS.** Evaluating the degree of conformity of papillary carcinoma and follicular carcinoma to the reported ultrasonographic findings of malignant thyroid tumor. *Korean J Radiol.* 2007;8:192-197. [EL 2]
98. **Kobayashi K, Fukata S, Miyauchi A.** Diagnosis of follicular carcinoma of the thyroid: role of sonography in preoperative diagnosis of follicular nodules. *J Med Ultrasonics.* 2005;32:153-158. [EL 2]
99. **Sillery JC, Reading CC, Charboneau JW, Henrichsen TL, Hay ID, Mandrekar JN.** Thyroid follicular carcinoma: sonographic features of 50 cases. *AJR Am J Roentgenol.* 2010;194:44-54. [EL 2]
100. **Gulcelik NE, Gulcelik MA, Kuru B.** Risk of malignancy in patients with follicular neoplasm: predictive value of clinical and ultrasonographic features. *Arch Otolaryngol Head Neck Surg.* 2008;134:1312-1315. [EL 2]
101. **Fukunari N, Nagahama M, Sugino K, Mimura T, Ito K, Ito K.** Clinical evaluation of color Doppler imaging for the differential diagnosis of thyroid follicular lesions. *World J Surg.* 2004;28:1261-1265. [EL 2]
102. **Shin JH, Han BK, Ko EY, Oh YL, Kim JH.** Differentiation of widely invasive and minimally invasive follicular thyroid carcinoma with sonography. *Eur J Radiol.* 2010;74:453-457. [EL 2]
103. **Maizlin ZV, Wiseman SM, Vora P, et al.** Hurthle cell neoplasms of the thyroid: sonographic appearance and histologic characteristics. *J Ultrasound Med.* 2008;27:751-757; quiz 759. [EL 3]
104. **Lee SK, Rho BH, Woo SK.** Hurthle cell neoplasm: correlation of gray-scale and power Doppler sonographic findings with gross pathology. *J Clin Ultrasound.* 2010;38:169-176. [EL 2]
105. **Choi N, Moon WJ, Lee JH, Baek JH, Kim DW, Park SW.** Ultrasonographic findings of medullary thyroid cancer: differences according to tumor size and correlation with fine needle aspiration results. *Acta Radiol.* 2011;52:312-316. [EL 3]
106. **Trimboli P, Giovanella L, Crescenzi A, et al.** Medullary thyroid cancer diagnosis: an appraisal. *Head Neck.* 2014;36:1216-1223. [EL 4]
107. **Rago T, Santini F, Scutari M, Pinchera A, Vitti P.** Elastography: new developments in ultrasound for predicting malignancy in thyroid nodules. *J Clin Endocrinol Metab.* 2007;92:2917-2922. [EL 3]
108. **Azizi G, Keller J, Lewis M, Puett D, Rivenbark K, Malchoff C.** Performance of elastography for the evaluation of thyroid nodules: a prospective study. *Thyroid.* 2013;23:734-740. [EL 3]
109. **Trimboli P, Guglielmi R, Monti S, et al.** Ultrasound sensitivity for thyroid malignancy is increased by real-time elastography: a prospective multicenter study. *J Clin Endocrinol Metab.* 2012;97:4524-4530. [EL 2]
110. **Ghajarzadeh M, Sodagari F, Shakiba M.** Diagnostic accuracy of sonoelastography in detecting malignant thyroid nodules: a systematic review and meta-analysis. *AJR Am J Roentgenol.* 2014;202:W379-W389. [EL 2]
111. **Russ G, Royer B, Bigorgne C, Rouxel A, Bienvenu-Perrard M, Leenhardt L.** Prospective evaluation of thyroid imaging reporting and data system on 4550 nodules with and without elastography. *Eur J Endocrinol.* 2013;168:649-655. [EL 2]
112. **Zhang YF, Liu C, Xu HX, et al.** Acoustic radiation force impulse imaging: a new tool for the diagnosis of papillary thyroid microcarcinoma. *Biomed Res Int.* 2014;2014:416969. [EL 2]
113. **Park AY, Son EJ, Han K, Youk JH, Kim JA, Park CS.** Shear wave elastography of thyroid nodules for the prediction of malignancy in a large scale study. *Eur J Radiol.* 2015;84:407-412. [EL 2]
114. **Liu BJ, Xu HX, Zhang YF, et al.** Acoustic radiation force impulse elastography for differentiation of benign and malignant thyroid nodules with concurrent Hashimoto's thyroiditis. *Med Oncol.* 2015;32:50. [EL 3]
115. **Rago T, Scutari M, Santini F, et al.** Real-time elastography: useful tool for refining the presurgical diagnosis in thyroid nodules with indeterminate or nondiagnostic cytology. *J Clin Endocrinol Metab.* 2010;95:5274-5280. [EL 2]
116. **Leenhardt L, Erdogan MF, Hegedüs L, et al.** 2013 European thyroid association guidelines for cervical ultrasound scan and ultrasound-guided techniques in the postoperative management of patients with thyroid cancer. *Eur Thyroid J.* 2013;2:147-159. [EL 4]
117. **Lepoutre-Lussey C, Maddah D, Golmard JL, et al.** Post-operative neck ultrasound and risk stratification in differentiated thyroid cancer patients with initial lymph node involvement. *Eur J Endocrinol.* 2014;170:837-846. [EL 2]
118. **Leenhardt L, Hejblum G, Franc B, et al.** Indications and limits of ultrasound-guided cytology in the management of nonpalpable thyroid nodules. *J Clin Endocrinol Metab.* 1999;84:24-28. [EL 2]
119. **Pacini F, Fugazzola L, Lippi F, et al.** Detection of thyroglobulin in fine needle aspirates of nonthyroidal neck masses: a clue to the diagnosis of metastatic differentiated thyroid cancer. *J Clin Endocrinol Metab.* 1992;74:1401-1404. [EL 2]
120. **Frasoldati A, Toschi E, Zini M, et al.** Role of thyroglobulin measurement in fine-needle aspiration biopsies of cervical lymph nodes in patients with differentiated thyroid cancer. *Thyroid.* 1999;9:105-111. [EL 2]
- 120b. **Kamaya A, Tahvildari AM, Patel B, Willman JK, Jeffrey B, Desser T.** Sonographic detection of extracapsular extension in papillary thyroid cancer. *JUM.* 2015;34:2225-2230. [EL 3]
121. **Moon SJ, Kim DW, Kim SJ, Ha TK, Park HK, Jung SJ.** Ultrasound assessment of degrees of extrathyroidal extension in papillary thyroid microcarcinoma. *Endocr Pract.* 2014;20:1037-1043. [EL 3]

122. **Roti E, degli Uberti EC, Bondanelli M, Braverman LE.** Thyroid papillary microcarcinoma: a descriptive and meta-analysis study. *Eur J Endocrinol.* 2008;159:659-673. [EL 4-review]
123. **Verburg FA, Mader U, Luster M, Reiners C.** Primary tumour diameter as a risk factor for advanced disease features of differentiated thyroid carcinoma. *Clin Endocrinol (Oxf).* 2009;71:291-297. [EL 3]
124. **Mandel SJ.** Diagnostic use of ultrasonography in patients with nodular thyroid disease. *Endocr Pract.* 2004;10:246-252. [EL 4-review]
125. **Ahn SS, Kim EK, Kang DR, Lim SK, Kwak JY, Kim MJ.** Biopsy of thyroid nodules: comparison of three sets of guidelines. *AJR Am J Roentgenol.* 2010;194:31-37. [EL 2]
126. **D'Orsi CJ, Sickles EA, Mendelson EB, Morris EA, et al.** *ACR BI-RADS® Atlas, Breast Imaging Reporting and Data System.* 4th ed. Reston, VA: American College of Radiology; 2003. [EL 4]
127. **Horvath E, Majlis S, Rossi R, et al.** An ultrasonogram reporting system for thyroid nodules stratifying cancer risk for clinical management. *J Clin Endocrinol Metab.* 2009;94:1748-1751. [EL 2]
128. **Kim DW, Park JS, In HS, Choo HJ, Ryu JH, Jung SJ.** Ultrasound-based diagnostic classification for solid and partially cystic thyroid nodules. *AJNR Am J Neuroradiol.* 2012;33:1144-1149. [EL 2]
129. **Lee YH, Kim DW, In HS, et al.** Differentiation between benign and malignant solid thyroid nodules using an US classification system. *Korean J Radiol.* 2011;12:559-567. [EL 2]
130. **Kwak JY, Han KH, Yoon JH, et al.** Thyroid imaging reporting and data system for US features of nodules: a step in establishing better stratification of cancer risk. *Radiology.* 2011;260:892-899. [EL 2]
131. **Russ G, Bigorgne C, Royer B, Rouxel A, Bienvenu-Perrard M.** The Thyroid Imaging Reporting and Data System (TIRADS) for ultrasound of the thyroid [in French]. *J Radiol.* 2011;92:701-713. [EL 3]
132. **Cosgrove D.** Future prospects for SonoVue and CPS. *Eur Radiol.* 2004;14 Suppl 8:P116-P124. [EL 4]
133. **Jiang J, Huang L, Zhang H, et al.** Contrast-enhanced sonography of thyroid nodules. *J Clin Ultrasound.* 2015;43:153-156. [EL 2]
134. **Ma JJ, Ding H, Xu BH, et al.** Diagnostic performances of various gray-scale, color Doppler, and contrast-enhanced ultrasonography findings in predicting malignant thyroid nodules. *Thyroid.* 2014;24:355-363. [EL 3]
135. **Papini E, Bizzarri G, Pacella CM.** Percutaneous laser ablation of benign and malignant thyroid nodules. *Curr Opin Endocrinol Diabetes Obes.* 2008;15:434-439. [EL 4-review]
136. **Weber AL, Randolph G, Aksoy FG.** The thyroid and parathyroid glands: CT and MR imaging and correlation with pathology and clinical findings. *Radiol Clin North Am.* 2000;38:1105-1129. [EL 4-review]
137. **Lee SY, Rhee CM, Leung AM, Braverman LE, Brent GA, Pearce EN.** A review: radiographic iodinated contrast media-induced thyroid dysfunction. *J Clin Endocrinol Metab.* 2015;100:376-383. [EL 4]
138. **de Groot JW, Links TP, Plukker JT, Lips CJ, Hofstra RM.** RET as a diagnostic and therapeutic target in sporadic and hereditary endocrine tumors. *Endocr Rev.* 2006;27:535-560. [EL 4]
139. **Giovanella L, Ceriani L, Treglia G.** Role of isotope scan, including positron emission tomography/computed tomography, in nodular goitre. *Best Pract Res Clin Endocrinol Metab.* 2014;28:507-518. [EL 4]
140. **Rago T, Scutari M, Latrofa F, et al.** The large majority of 1520 patients with indeterminate thyroid nodule at cytology have a favorable outcome, and a clinical risk score has a high negative predictive value for a more cumbersome cancer disease. *J Clin Endocrinol Metab.* 2014;99:3700-3707. [EL 2]
- 140b. **Nikivorov YE, Carty SE, Chiosea SI, et al.** Highly accurate diagnosis of cancer in thyroid nodules with follicular neoplasm/suspicious for a follicular neoplasm cytology by ThyroSeq v2 next-generation sequencing assay. *Cancer.* 2014;120:3627-3634. [EL 2]
141. **Ali SZ, Cibas ES, eds.** *The Bethesda System for Reporting Thyroid Cytopathology: Definitions, Criteria and Explanatory Notes.* New York, NY: Springer; 2010. [EL 4]
142. **Hor T, Lahiri SW.** Bilateral thyroid hematomas after fine-needle aspiration causing acute airway obstruction. *Thyroid.* 2008;18:567-569. [EL 3]
143. **Lee YH, Baek JH, Jung SL, et al.** Ultrasound-guided fine needle aspiration of thyroid nodules: a consensus statement by the Korean Society of Thyroid Radiology. *Korean J Radiol.* 2015;16:391-401. [EL 4]
144. **Abu-Yousef MM, Larson JH, Kuehn DM, Wu AS, Laroia AT.** Safety of ultrasound-guided fine needle aspiration biopsy of neck lesions in patients taking antithrombotic/anticoagulant medications. *Ultrasound Q.* 2011;27:157-159. [EL 2]
145. **Wu HH, Jones JN, Osman J.** Fine-needle aspiration cytology of the thyroid: ten years experience in a community teaching hospital. *Diagn Cytopathol.* 2006;34:93-96. [EL 3]
146. **Danese D, Sciacchitano S, Farsetti A, Andreoli M, Pontecorvi A.** Diagnostic accuracy of conventional versus sonography-guided fine-needle aspiration biopsy of thyroid nodules. *Thyroid.* 1998;8:15-21. [EL 4]
147. **Deandrea M, Mormile A, Veglio M, et al.** Fine-needle aspiration biopsy of the thyroid: comparison between thyroid palpation and ultrasonography. *Endocr Pract.* 2002;8:282-286. [EL 3]
148. **Can AS, Peker K.** Comparison of palpation-versus ultrasound-guided fine-needle aspiration biopsies in the evaluation of thyroid nodules. *BMC Res Notes.* 2008;1:12. [EL 4]
149. **Pitman MB, Abele J, Ali SZ, et al.** Techniques for thyroid FNA: a synopsis of the National Cancer Institute thyroid fine-needle aspiration state of the science conference. *Diagn Cytopathol.* 2008;36:407-424. [EL 4]
150. **Guidance on the reporting of thyroid cytology specimens [Internet].** London, UK: The Royal College of Pathologists; 2009. Available at: <http://www.rcpath.org/Resources/RCPATH/Migrated%20Resources/Documents/G/g089guidanceonthereportingofthyroidcytologyfinal.pdf>. Accessed April 29, 2015. [EL 4]
151. **Baloch ZW, LiVolsi VA, Asa SL, et al.** Diagnostic terminology and morphologic criteria for cytologic diagnosis of thyroid lesions: a synopsis of the National Cancer Institute thyroid fine-needle aspiration state of the science conference. *Diagn Cytopathol.* 2008;36:425-437. [EL 4-consensus]
152. **Nardi F, Basolo F, Crescenzi A, et al.** Italian consensus for the classification and reporting of thyroid cytology. *J Endocrinol Invest.* 2014;37:593-599. [EL 4]

153. **Moon JH, Kim YI, Lim JA, et al.** Thyroglobulin in washout fluid from lymph node fine-needle aspiration biopsy in papillary thyroid cancer: large-scale validation of the cutoff value to determine malignancy and evaluation of discrepant results. *J Clin Endocrinol Metab.* 2013;98:1061-1068. [EL 3]
154. **Bongiovanni M, Spitale A, Faquin WC, Mazzucchelli L, Baloch ZW.** The Bethesda system for reporting thyroid cytopathology: a meta-analysis. *Acta Cytol.* 2012;56:333-339. [EL 2]
155. **Cross PA, Poller D.** The Bethesda thyroid terminology and progress towards international agreement on thyroid FNA cytology reporting. *Cytopathology.* 2010;21:71-74. [EL 4]
156. **DeMay RM.** Thyroid. In: *The Art and Science of Cytopathology.* Vol II. Chicago, IL: American Society of Clinical Pathologists; 1996: Chapter 17. [EL 4]
157. **Kini SR.** Specimen adequacy and assessment, reporting system. In: *Thyroid Cytopathology: An Atlas and Text.* Philadelphia, PA: Lippincott, Williams & Wilkins; 2008: 17-26. [EL 4]
158. **Redman R, Zalaznick H, Mazzaferri EL, Massoll NA.** The impact of assessing specimen adequacy and number of needle passes for fine-needle aspiration biopsy of thyroid nodules. *Thyroid.* 2006;16:55-60. [EL 3]
159. **Piana S, Frasoldati A, Ferrari M, et al.** Is a five-category reporting scheme for thyroid fine needle aspiration cytology accurate? Experience of over 18,000 FNAs reported at the same institution during 1998-2007. *Cytopathology.* 2011;22:164-173. [EL 3]
160. **Bongiovanni M, Crippa S, Baloch Z, et al.** Comparison of 5-tiered and 6-tiered diagnostic systems for the reporting of thyroid cytopathology: a multi-institutional study. *Cancer Cytopathol.* 2012;120:117-125. [EL 2]
161. **Yang J, Schnadig V, Logrono R, Wasserman PG.** Fine-needle aspiration of thyroid nodules: a study of 4703 patients with histologic and clinical correlations. *Cancer.* 2007;111:306-315. [EL 3]
162. **Renshaw AA.** Should "atypical follicular cells" in thyroid fine-needle aspirates be subclassified? *Cancer Cytopathol.* 2010;118:186-189. Erratum in: *Cancer Cytopathol.* 2010; 118:303. [EL 3]
163. **VanderLaan PA, Marqusee E, Krane JF.** Usefulness of diagnostic qualifiers for thyroid fine-needle aspirations with atypia of undetermined significance. *Am J Clin Pathol.* 2011;136:572-577. [EL 3]
164. **Singh RS, Wang HH.** Eliminating the "atypia of undetermined significance/follicular lesion of undetermined significance" category from the Bethesda system for reporting thyroid cytopathology. *Am J Clin Pathol.* 2011;136: 896-902. [EL 4]
165. **Kocjan G, Chandra A, Cross PA, et al.** The interobserver reproducibility of thyroid fine-needle aspiration using the UK Royal College of Pathologists' classification system. *Am J Clin Pathol.* 2011;135:852-859. [EL 3]
166. **Hamberger B, Gharib H, Melton LJ 3rd, Goellner JR, Zinsmeister AR.** Fine-needle aspiration biopsy of thyroid nodules: impact on thyroid practice and cost of care. *Am J Med.* 1982;73:381-384. [EL 3]
167. **Kwak JY, Kim EK, Kim HJ, Kim MJ, Son EJ, Moon HJ.** How to combine ultrasound and cytological information in decision making about thyroid nodules. *Eur Radiol.* 2009;19:1923-1931. [EL 3]
168. **Orlandi A, Puscar A, Capriata E, Fideleff H.** Repeated fine-needle aspiration of the thyroid in benign nodular thyroid disease: critical evaluation of long-term follow-up. *Thyroid.* 2005;15:274-278. [EL 3]
169. **Menéndez Torre E, Pineda Arribas J, Martínez de Esteban JP, López Carballo MT, de Miguel C, Salvador P.** Value of repeated fine needle aspiration cytology in patients with nodular goiter. *Acta Cytol.* 2007;51:850-852. [EL 3]
170. **Frasoldati A, Toschi E, Zini M, et al.** Role of thyroglobulin measurement in fine-needle aspiration biopsies of cervical lymph nodes in patients with differentiated thyroid cancer. *Thyroid.* 1999;9:105-111. [EL 3]
171. **Pacini F, Fugazzola L, Lippi F, et al.** Detection of thyroglobulin in fine needle aspirates of nonthyroidal neck masses: a clue to the diagnosis of metastatic differentiated thyroid cancer. *J Clin Endocrinol Metab.* 1992;74:1401-1404. [EL 3]
172. **Urano T, Miyauchi A, Shimizu K, et al.** Usefulness of thyroglobulin measurement in fine-needle aspiration biopsy specimens for diagnosing cervical lymph node metastasis in patients with papillary thyroid cancer. *World J Surg.* 2005;29:483-485. [EL 3]
173. **Baskin HJ.** Detection of recurrent papillary thyroid carcinoma by thyroglobulin assessment in the needle washout after fine-needle aspiration of suspicious lymph nodes. *Thyroid.* 2004;14:959-963. [EL 3]
174. **Snozek CL, Chambers EP, Reading CC, et al.** Serum thyroglobulin, high-resolution ultrasound, and lymph node thyroglobulin in diagnosis of differentiated thyroid carcinoma nodal metastases. *J Clin Endocrinol Metab.* 2007;92:4278-4281. [EL 2]
175. **Cunha N, Rodrigues F, Curado F, et al.** Thyroglobulin detection in fine-needle aspirates of cervical lymph nodes: a technique for the diagnosis of metastatic differentiated thyroid cancer. *Eur J Endocrinol.* 2007;157:101-107. [EL 3]
176. **Baloch ZW, Barroeta JE, Walsh J, et al.** Utility of thyroglobulin measurement in fine-needle aspiration biopsy specimens of lymph nodes in the diagnosis of recurrent thyroid carcinoma. *Cytojournal.* 2008;5:1. [EL 2]
177. **Kim MJ, Kim EK, Kim BM, et al.** Thyroglobulin measurement in fine-needle aspirate washouts: the criteria for neck node dissection for patients with thyroid cancer. *Clin Endocrinol (Oxf).* 2009;70:145-151. [EL 3]
178. **Torres MR, Nóbrega Neto SH, Rosas RJ, et al.** Thyroglobulin in the washout fluid of lymph-node biopsy: what is its role in the follow-up of differentiated thyroid carcinoma? *Thyroid.* 2014;24:7-18. [EL 4]
179. **Grani G, Fumarola A.** Thyroglobulin in lymph node fine-needle aspiration washout: a systematic review and meta-analysis of diagnostic accuracy. *J Clin Endocrinol Metab.* 2014;99:1970-1982. [EL 2]
180. **Lee YH, Seo HS, Suh SI, et al.** Cut-off value for needle washout thyroglobulin in athyrotropic patients. *Laryngoscope.* 2010;120:1120-1124. [EL 3]
181. **Bournaud C, Charrié A, Nozières C, et al.** Thyroglobulin measurement in fine-needle aspirates of lymph nodes in patients with differentiated thyroid cancer: a simple definition of the threshold value, with emphasis on potential pitfalls of the method. *Clin Chem Lab Med.* 2010;48:1171-1177. [EL 3]
182. **Giovanella L, Bongiovanni M, Trimboli P.** Diagnostic value of thyroglobulin assay in cervical lymph node fine-needle aspirations for metastatic differentiated thyroid cancer. *Curr Opin Oncol.* 2013;25:6-13. [EL 4]

183. **Jung JY, Shin JH, Han BK, Ko EY.** Optimized cut-off value and indication for washout thyroglobulin level according to ultrasound findings in patients with well-differentiated thyroid cancer. *AJNR Am J Neuroradiol.* 2013;34:2349-2353. [EL 3]
184. **Boi F, Baghino G, Atzeni F, Lai ML, Faa G, Mariotti S.** The diagnostic value for differentiated thyroid carcinoma metastases of thyroglobulin (Tg) measurement in wash-out fluid from fine-needle aspiration biopsy of neck lymph nodes is maintained in the presence of circulating anti-Tg antibodies. *J Clin Endocrinol Metab.* 2006;91:1364-1369. [EL 3]
185. **Jeon MJ, Park JW, Han JM, et al.** Serum antithyroglobulin antibodies interfere with thyroglobulin detection in fine-needle aspirates of metastatic neck nodes in papillary thyroid carcinoma. *J Clin Endocrinol Metab.* 2013;98:153-160. [EL 2]
186. **Boi F, Maurelli I, Pinna G, et al.** Calcitonin measurement in wash-out fluid from fine needle aspiration of neck masses in patients with primary and metastatic medullary thyroid carcinoma. *J Clin Endocrinol Metab.* 2007;92:2115-2118. [EL 3]
187. **Kudo T, Miyauchi A, Ito Y, Takamura Y, Amino N, Hirokawa M.** Diagnosis of medullary thyroid carcinoma by calcitonin measurement in fine-needle aspiration biopsy specimens. *Thyroid.* 2007;17:635-638. [EL 3]
188. **Abraham D, Gault PM, Hunt J, Bentz J.** Calcitonin estimation in neck lymph node fine-needle aspirate fluid prevents misinterpretation of cytology in patients with metastatic medullary thyroid cancer. *Thyroid.* 2009;19:1015-1016. [EL 3]
189. **Trimboli P, Cremonini N, Ceriani L, et al.** Calcitonin measurement in aspiration needle washout fluids has higher sensitivity than cytology in detecting medullary thyroid cancer: a retrospective multicentre study. *Clin Endocrinol (Oxf).* 2014;80:135-140. [EL 2]
190. **Marcocci C, Mazzeo S, Bruno-Bossio G, et al.** Preoperative localization of suspicious parathyroid adenomas by assay of parathyroid hormone in needle aspirates. *Eur J Endocrinol.* 1998;139:72-77. [EL 3]
191. **Kiblut NK, Cussac JF, Soudan B, et al.** Fine needle aspiration and intraparathyroid intact parathyroid hormone measurement for reoperative parathyroid surgery. *World J Surg.* 2004;28:1143-1147. [EL 3]
192. **Maser C, Donovan P, Santos F, et al.** Sonographically guided fine needle aspiration with rapid parathyroid hormone assay. *Ann Surg Oncol.* 2006;13:1690-1695. [EL 2]
193. **Erbil Y, Salmaslioglu A, Kabul E, et al.** Use of preoperative parathyroid fine-needle aspiration and parathormone assay in the primary hyperparathyroidism with concomitant thyroid nodules. *Am J Surg.* 2007;193:665-671. [EL 3]
194. **Owens CL, Rekhman N, Sokoll L, Ali SZ.** Parathyroid hormone assay in fine-needle aspirate is useful in differentiating inadvertently sampled parathyroid tissue from thyroid lesions. *Diagn Cytopathol.* 2008;36:227-231. [EL 3]
195. **Kwak JY, Kim EK, Moon HJ, et al.** Parathyroid incidentalomas detected on routine ultrasound-directed fine-needle aspiration biopsy in patients referred for thyroid nodules and the role of parathyroid hormone analysis in the samples. *Thyroid.* 2009;19:743-748. [EL 3]
196. **Renshaw AA, Pinnar N.** Comparison of thyroid fine-needle aspiration and core needle biopsy. *Am J Clin Pathol.* 2007;128:370-374. [EL 3]
197. **Choi SH, Baek JH, Lee JH, et al.** Thyroid nodules with initially non-diagnostic, fine-needle aspiration results: comparison of core-needle biopsy and repeated fine-needle aspiration. *Eur Radiol.* 2014;24:2819-2826. [EL 2]
198. **Zhang S, Ivanovic M, Nemcek AA Jr, Defrias DV, Lucas E, Nayar R.** Thin core needle biopsy crush preparations in conjunction with fine-needle aspiration for the evaluation of thyroid nodules: a complementary approach. *Cancer.* 2008;114:512-518. [EL 3]
199. **Yoon RG, Baek JH, Lee JH, et al.** Diagnosis of thyroid follicular neoplasm: fine-needle aspiration versus core-needle biopsy. *Thyroid.* 2014;24:1612-1617. [EL 2]
200. **Nasrollah N, Trimboli P, Guidobaldi L, et al.** Thin core biopsy should help to discriminate thyroid nodules cytologically classified as indeterminate: a new sampling technique. *Endocrine.* 2013;43:659-665. [EL 3]
201. **Bartolazzi A, Orlandi F, Saggiorato E, et al.** Galectin-3-expression analysis in the surgical selection of follicular thyroid nodules with indeterminate fine-needle aspiration cytology: a prospective multicentre study. *Lancet Oncol.* 2008;9:543-549. [EL 2]
202. **de Matos PS, Ferreira AP, de Oliveira Facuri F, Assumpção LV, Metze K, Ward LS.** Usefulness of HBME-1, cytokeratin 19 and galectin-3 immunostaining in the diagnosis of thyroid malignancy. *Histopathology.* 2005;47:391-401. [EL 2]
203. **Saggiorato E, De Pompa R, Volante M, et al.** Characterization of thyroid 'follicular neoplasms' in fine-needle aspiration cytological specimens using a panel of immunohistochemical markers: a proposal for clinical application. *Endocr Relat Cancer.* 2005;12:305-317. [EL 2]
204. **Takano T, Miyauchi A, Matsuzuka F, Yoshida H, Kuma K, Amino N.** Ubiquitous expression of galectin-3 mRNA in benign and malignant thyroid tumors. *Cancer Lett.* 2003;199:69-73. [EL 3]
205. **Volante M, Bozzalla-Cassione F, DePompa R, et al.** Galectin-3 and HBME-1 expression in oncocytic cell tumors of the thyroid. *Virchows Arch.* 2004;445:183-188. [EL 3]
206. **Faggiano A, Caillou B, Lacroix L, et al.** Functional characterization of human thyroid tissue with immunohistochemistry. *Thyroid.* 2007;17:203-211. [EL 4]
207. **Freitas BC, Cerutti JM.** Genetic markers differentiating follicular thyroid carcinoma from benign lesions. *Mol Cell Endocrinol.* 2010;321:77-85. [EL 4]
208. **de Matos LL, Del Giglio AB, Matsubayashi CO, de Lima Farah M, Del Giglio A, da Silva Pinhal MA.** Expression of CK-19, galectin-3 and HBME-1 in the differentiation of thyroid lesions: systematic review and diagnostic meta-analysis. *Diagn Pathol.* 2012;7:97. [EL 4]
209. **Cibas ES, Baloch ZW, Fellegara G, et al.** A prospective assessment defining the limitations of thyroid nodule pathologic evaluation. *Ann Intern Med.* 2013;159:325-332. [EL 2]
210. **Nikiforov YE, Ohori NP, Hodak SP, et al.** Impact of mutational testing on the diagnosis and management of patients with cytologically indeterminate thyroid nodules: a prospective analysis of 1056 FNA samples. *J Clin Endocrinol Metab.* 2011;96:3390-3397. [EL 2]
211. **Nikiforov YE, Steward DL, Robinson-Smith TM, et al.** Molecular testing for mutations in improving the fine-needle aspiration diagnosis of thyroid nodules. *J Clin Endocrinol Metab.* 2009;94:2092-2098. [EL 2]

212. **Cantara S, Capezzone M, Marchisotta S, et al.** Impact of proto-oncogene mutation detection in cytological specimens from thyroid nodules improves the diagnostic accuracy of cytology. *J Clin Endocrinol Metab.* 2010;95:1365-1369. [EL 2]
213. **Eszlinger M, Krogdahl A, Munz S, et al.** Impact of molecular screening for point mutations and rearrangements in routine air-dried fine-needle aspiration samples of thyroid nodules. *Thyroid.* 2014;24:305-313. [EL 2]
214. **Alexander EK, Kennedy GC, Baloch ZW, et al.** Preoperative diagnosis of benign thyroid nodules with indeterminate cytology. *N Engl J Med.* 2012;367:705-715. [EL 2]
- 214b. **McIver B.** Evaluation of the thyroid nodule. *Oral Oncol.* 2013;49:645-653. [EL 4]
215. **Harrell RM, Bimston DN.** Surgical utility of Afirma: effects of high cancer prevalence and oncocyctic cell types in patients with indeterminate thyroid cytology. *Endocr Pract.* 2014;20:364-369. [EL 2]
216. **Eszlinger M, Hegedüs L, Paschke R.** Ruling in or ruling out thyroid malignancy by molecular diagnostics of thyroid nodules. *Best Pract Res Clin Endocrinol Metab.* 2014;28:545-557. [EL 4]
217. **Cancer Genome Atlas Research Network.** Integrated genomic characterization of papillary thyroid carcinoma. *Cell.* 2014;159:676-690. [EL 3]
218. **Melo M, da Rocha AG, Vinagre J, et al.** TERT promoter mutations are a major indicator of poor outcome in differentiated thyroid carcinomas. *J Clin Endocrinol Metab.* 2014;99:E754-E765. [EL 2]
219. **Liu R, Xing M.** Diagnostic and prognostic TERT promoter mutations in thyroid fine-needle aspiration biopsy. *Endocr Relat Cancer.* 2014;21:825-830. [EL 2]
220. **Spencer CA, Takeuchi M, Kazarosyan M.** Current status and performance goals for serum thyrotropin (TSH) assays. *Clin Chem.* 1996;42:140-145. [EL 4-review]
- 220b. **Völzke H, Alte D, Kohlmann T, et al.** Reference intervals of serum thyroid function tests in a previously iodine-deficient area. *Thyroid.* 2005;15:279-285. [EL 2]
- 220c. **Völzke H, Schmidt Co, John U, et al.** Reference levels for serum thyroid function tests of diagnostic and prognostic significance. *Horm Metab Res.* 2010;42:809-814. [EL 2]
221. **Baloch Z, Carayon P, Conte-Devolx B, et al.** Laboratory medicine practice guidelines: laboratory support for the diagnosis and monitoring of thyroid disease. *Thyroid.* 2003;13:3-126. [EL 4-guidelines]
222. **Ross DS.** Laboratory assessment of thyroid function [Internet]. UpToDate: Cooper DS, Mulder JE, eds. 2015 [last updated 2014 Dec 19]. Available at: <http://www.uptodate.com/contents/laboratory-assessment-of-thyroid-function>. Accessed on April 29, 2015. [EL 4-review]
223. **Hegedüs L, Bonnema SJ, Bennedbaek FN.** Management of simple nodular goiter: current status and future perspectives. *Endocr Rev.* 2003;24:102-32. [EL 4-review]
224. **Carle A, Pedersen IB, Knudsen N, et al.** Thyroid volume in hypothyroidism due to autoimmune disease follows a unimodal distribution: evidence against primary thyroid atrophy and autoimmune thyroiditis being distinct diseases. *J Clin Endocrinol Metab.* 2009;94:833-839. [EL 3]
225. **Wallaschofski H, Orda C, Georgi P, Miehle K, Paschke R.** Distinction between autoimmune and non-autoimmune hyperthyroidism by determination of TSH-receptor antibodies in patients with the initial diagnosis of toxic multinodular goiter. *Horm Metab Res.* 2001;33:504-507. [EL 3]
226. **Pedersen IB, Knudsen N, Perrild H, Ovesen L, Laurberg P.** TSH-receptor antibody measurement for differentiation of hyperthyroidism into Graves' disease and multinodular toxic goitre: a comparison of two competitive binding assays. *Clin Endocrinol (Oxf).* 2001;55:381-390. [EL 3]
227. **Date J, Feldt-Rasmussen U, Blichert-Toft M, Hegedüs L, Graversen HP.** Long-term observation of serum thyroglobulin after resection of nontoxic goiter and relation to ultrasonographically demonstrated relapse. *World J Surg.* 1996;20:351-356; discussion 357. [EL 3]
228. **Giovanella L, Ceriani L, Ghelfo A, Maffioli M, Keller F.** Preoperative undetectable serum thyroglobulin in differentiated thyroid carcinoma: incidence, causes and management strategy. *Clin Endocrinol (Oxf).* 2007;67:547-551. [EL 3]
229. **Cohen R, Campos JM, Salaün C, et al.** Preoperative calcitonin levels are predictive of tumor size and postoperative calcitonin normalization in medullary thyroid carcinoma. Groupe d'Etudes des Tumeurs a Calcitonine (GETC). *J Clin Endocrinol Metab.* 2000;85:919-922. [EL 3]
230. **Elisei R, Bottici V, Luchetti F, et al.** Impact of routine measurement of serum calcitonin on the diagnosis and outcome of medullary thyroid cancer: experience in 10,864 patients with nodular thyroid disorders. *J Clin Endocrinol Metab.* 2004;89:163-168. [EL 3]
231. **Brandi ML, Gagel RF, Angeli A, et al.** Guidelines for diagnosis and therapy of MEN type 1 and type 2. *J Clin Endocrinol Metab.* 2001;86:5658-5671. [EL 4-guidelines]
232. **Costante G, Meringolo D, Durante C, et al.** Predictive value of serum calcitonin levels for preoperative diagnosis of medullary thyroid carcinoma in a cohort of 5817 consecutive patients with thyroid nodules. *J Clin Endocrinol Metab.* 2007;92:450-455. [EL 2]
233. **Cheung K, Roman SA, Wang TS, Walker HD, Sosa JA.** Calcitonin measurement in the evaluation of thyroid nodules in the United States: a cost-effectiveness and decision analysis. *J Clin Endocrinol Metab.* 2008;93:2173-2180. [EL 3]
234. **Cooper DS, Doherty GM, Haugen BR, et al.** Management guidelines for patients with thyroid nodules and differentiated thyroid cancer. *Thyroid.* 2006;16:109-142. [EL 4-guidelines]
235. **Machens A, Hoffmann F, Sekulla C, Dralle H.** Importance of gender-specific calcitonin thresholds in screening for occult sporadic medullary thyroid cancer. *Endocr Relat Cancer.* 2009;16:1291-1298. [EL 3]
236. **d'Herbomez M, Caron P, Bauters C, et al.** Reference range of serum calcitonin levels in humans: influence of calcitonin assays, sex, age, and cigarette smoking. *Eur J Endocrinol.* 2007;157:749-755. [EL 3]
237. **Karges W, Dralle H, Raue F, et al.** Calcitonin measurement to detect medullary thyroid carcinoma in nodular goiter: German evidence-based consensus recommendation. *Exp Clin Endocrinol Diabetes.* 2004;112:52-58. [EL 3]
238. **Rink T, Truong PN, Schroth HJ, Diener J, Zimny M, Grünwald F.** Calculation and validation of a plasma calcitonin limit for early detection of medullary thyroid carcinoma in nodular thyroid disease. *Thyroid.* 2009;19:327-332. [EL 3]

239. **Mian C, Perrino M, Colombo C, et al.** Refining calcium test for the diagnosis of medullary thyroid cancer: cutoffs, procedures, and safety. *J Clin Endocrinol Metab.* 2014;99:1656-1664. [EL 3]
240. **Doyle P, Duren C, Nerlich K, et al.** Potency and tolerance of calcitonin stimulation with high-dose calcium versus pentagastrin in normal adults. *J Clin Endocrinol Metab.* 2009;94:2970-2974. Erratum in: *J Clin Endocrinol Metab.* 2009;94:4629. [EL 2]
- 240b. **Russo M, Scollo C, Padova G, Vigneri R, Pellegriti G.** Cardiac arrest after intravenous calcium administration for calcitonin stimulation test. *Thyroid.* 2014;24:606-607. [EL 4].
241. **Colombo C, Verga U, Mian C, et al.** Comparison of calcium and pentagastrin tests for the diagnosis and follow-up of medullary thyroid cancer. *J Clin Endocrinol Metab.* 2012;97:905-913. [EL 3]
242. **Wohlk N, Cote GJ, Bugalho MM, et al.** Relevance of RET proto-oncogene mutations in sporadic medullary thyroid carcinoma. *J Clin Endocrinol Metab.* 1996;81:3740-3745. [EL 3]
243. **Elisei R, Alevizaki M, Conte-Devolx B, Frank-Raue K, Leite V, Williams GR.** 2012 European thyroid association guidelines for genetic testing and its clinical consequences in medullary thyroid cancer. *Eur Thyroid J.* 2013;1:216-231. [EL 4]
244. **McHenry CR, Slusarczyk SJ, Askari AT, et al.** Refined use of scintigraphy in the evaluation of nodular thyroid disease. *Surgery.* 1998;124:656-661; discussion 661-662. [EL 3]
245. **Meier DA, Kaplan MM.** Radioiodine uptake and thyroid scintiscanning. *Endocrinol Metab Clin North Am.* 2001;30:291-313, viii. [EL 4-review]
246. **Bonnema SJ, Bennedbaek FN, Hegedüs L.** Danish endocrinologists' examination and treatment of non-toxic multinodular goiter: a questionnaire study [in Danish]. *Ugeskr Laeger.* 2001;163:1265-1269. [EL 3]
247. **Hillenhinrichs H, Emrich D.** Euthyroid goiter with and without functional autonomy in the euthyroid phase: a comparison [in German]. *Nuklearmedizin.* 1998;37:95-100. [EL 3]
248. **Tollin SR, Fallon EF, Mikhail M, Goldstein H, Yung E.** The utility of thyroid nuclear imaging and other studies in the detection and treatment of underlying thyroid abnormalities in patients with endogenous subclinical thyrotoxicosis. *Clin Nucl Med.* 2000;25:341-347. [EL 3]
249. **Krohn K, Wohlgemuth S, Gerber H, Paschke R.** Hot microscopic areas of iodine-deficient euthyroid goitres contain constitutively activating TSH receptor mutations. *J Pathol.* 2000;192:37-42. [EL 3]
- 249b. **Pacella CM, Mauri G, Achille, G et al.** Outcomes and risk factors for complications of laser ablation for thyroid nodules. A multicenter study on 1531 patients. *J Clin Endocrinol Metab.* 2015;100:3903-3910. [EL 3]
250. **Choi YS, Hong SW, Kwak JY, Moon HJ, Kim EK.** Clinical and ultrasonographic findings affecting nondiagnostic results upon the second fine needle aspiration for thyroid nodules. *Ann Surg Oncol.* 2012;19:2304-2309. [EL 3]
251. **Singh RS, Wang HH.** Timing of repeat thyroid fine-needle aspiration in the management of thyroid nodules. *Acta Cytol.* 2011;55:544-548. [EL 3]
252. **Baloch ZW, LiVolsi VA.** Post fine-needle aspiration histologic alterations of thyroid revisited. *Am J Clin Pathol.* 1999;112:311-316. [EL 4]
253. **Na DG, Kim JH, Sung JY, et al.** Core-needle biopsy is more useful than repeat fine-needle aspiration in thyroid nodules read as nondiagnostic or atypia of undetermined significance by the Bethesda system for reporting thyroid cytopathology. *Thyroid.* 2012;22:468-475. [EL 3]
254. **van Roosmalen J, van Hemel B, Suurmeijer A, et al.** Diagnostic value and cost considerations of routine fine-needle aspirations in the follow-up of thyroid nodules with benign readings. *Thyroid.* 2010;20:1359-1365. [EL 2]
255. **Porterfield JR Jr, Grant CS, Dean DS, et al.** Reliability of benign fine needle aspiration cytology of large thyroid nodules. *Surgery.* 2008;144:963-968; discussion 968-969. [EL 3]
256. **Yoon JH, Kwak JY, Moon HJ, Kim MJ, Kim EK.** The diagnostic accuracy of ultrasound-guided fine-needle aspiration biopsy and the sonographic differences between benign and malignant thyroid nodules 3 cm or larger. *Thyroid.* 2011;21:993-1000. [EL 2]
257. **Gharib H, James EM, Charboneau JW, Naessens JM, Offord KP, Gorman CA.** Suppressive therapy with levothyroxine for solitary thyroid nodules: a double-blind controlled clinical study. *N Engl J Med.* 1987;317:70-75. [EL 1]
258. **La Rosa GL, Ippolito AM, Lupo L, et al.** Cold thyroid nodule reduction with L-thyroxine can be predicted by initial nodule volume and cytological characteristics. *J Clin Endocrinol Metab.* 1996;81:4385-4387. [EL 2]
259. **Grussendorf M, Reiners C, Paschke R, Wegscheider K; LISA Investigators.** Reduction of thyroid nodule volume by levothyroxine and iodine alone and in combination: a randomized, placebo-controlled trial. *J Clin Endocrinol Metab.* 2011;96:2786-2795. [EL 1]
260. **Wémeau JL, Caron P, Schwartz C, et al.** Effects of thyroid-stimulating hormone suppression with levothyroxine in reducing the volume of solitary thyroid nodules and improving extranodular nonpalpable changes: a randomized, double-blind, placebo-controlled trial by the French Thyroid Research Group. *J Clin Endocrinol Metab.* 2002;87:4928-4934. [EL 1]
261. **Hegedüs L, Nygaard B, Hansen JM.** Is routine thyroxine treatment to hinder postoperative recurrence of nontoxic goiter justified? *J Clin Endocrinol Metab.* 1999;84:756-760. [EL 2]
262. **Moalem J, Suh I, Duh QY.** Treatment and prevention of recurrence of multinodular goiter: an evidence-based review of the literature. *World J Surg.* 2008;32:1301-1312. [EL 4]
- 262b. **Fogelfeld L, Wiviott MB, Shore-Freedman E, et al.** Recurrence of thyroid nodules after surgical removal in patients irradiated in childhood for benign conditions. *N Engl J Med.* 1989;30:320:835-840. [EL 3]
263. **Faber J, Galloe AM.** Changes in bone mass during prolonged subclinical hyperthyroidism due to L-thyroxine treatment: a meta-analysis. *Eur J Endocrinol.* 1994;130:350-356. [EL 1]
264. **Uzzan B, Campos J, Cucherat M, Nony P, Boissel JP, Perret GY.** Effects on bone mass of long term treatment with thyroid hormones: a meta-analysis. *J Clin Endocrinol Metab.* 1996;81:4278-4289. [EL 1]
265. **Abrahamsen B, Jorgensen HL, Laulund AS, Nybo M, Brix TH, Hegedüs L.** Low serum thyrotropin level and duration of suppression as a predictor of major osteoporotic fractures: the OPENTHYRO register cohort. *J Bone Miner Res.* 2014;29:2040-2050. [EL 2]



266. Selmer C, Olesen JB, Hansen ML, et al. The spectrum of thyroid disease and risk of new onset atrial fibrillation: a large population cohort study. *BMJ.* 2012;345:e7895. [EL 2]
267. Parle JV, Maisonneuve P, Sheppard MC, Boyle P, Franklyn JA. Prediction of all-cause and cardiovascular mortality in elderly people from one low serum thyrotropin result: a 10-year cohort study. *Lancet.* 2001;358:861-865. [EL 2]
268. Brandt F, Almind D, Christensen K, Green A, Brix TH, Hegedüs L. Excess mortality in hyperthyroidism: the influence of preexisting comorbidity and genetic confounding: a Danish nationwide register-based cohort study of twins and singletons. *J Clin Endocrinol Metab.* 2012;97:4123-4129. [EL 2]
269. Laulund AS, Nybo M, Brix TH, Abrahamsen B, Jorgensen HL, Hegedüs L. Duration of thyroid dysfunction correlates with all-cause mortality: the OPENTHYRO Register Cohort. *PLoS One.* 2014;9:e110437. [EL 2]
270. Fast S, Bonnema SJ, Hegedüs L. The majority of Danish nontoxic goiter patients are ineligible for Levothyroxine suppressive therapy. *Clin Endocrinol (Oxf).* 2008;69:653-658. [EL 3]
271. Fiore E, Rago T, Provenzale MA, et al. L-thyroxine-treated patients with nodular goiter have lower serum TSH and lower frequency of papillary thyroid cancer: results of a cross-sectional study on 27,914 patients. *Endocr Relat Cancer.* 2010;17:231-239. [EL 3]
272. Dralle H, Machens A, Thanh PN. Minimally invasive compared with conventional thyroidectomy for nodular goitre. *Best Pract Res Clin Endocrinol Metab.* 2014;28:589-599. [EL 4]
273. Miccoli P, Minuto MN, Ugolini C, Pisano R, Fosso A, Berti P. Minimally invasive video-assisted thyroidectomy for benign thyroid disease: an evidence-based review. *World J Surg.* 2008;32:1333-1340. [EL 4-review]
274. Lombardi CP, Raffaelli M, Princi P, De Crea C, Bellantone R. Minimally invasive video-assisted functional lateral neck dissection for metastatic papillary thyroid carcinoma. *Am J Surg.* 2007 Jan;193(1):114-8. [EL 4]
275. Papini E, Pacella CM, Misichi I, et al. The advent of ultrasound-guided ablation techniques in nodular thyroid disease: towards a patient-tailored approach. *Best Pract Res Clin Endocrinol Metab.* 2014;28:601-618. [EL 4]
276. Gharib H, Hegedüs L, Pacella CM, Baek JH, Papini E. Clinical review: nonsurgical, image-guided, minimally invasive therapy for thyroid nodules. *J Clin Endocrinol Metab.* 2013;98:3949-3957. [EL 4]
277. Verde G, Papini E, Pacella CM, et al. Ultrasound guided percutaneous ethanol injection in the treatment of cystic thyroid nodules. *Clin Endocrinol (Oxf).* 1994;41:719-724. [EL 1]
278. Zingrillo M, Torlontano M, Chiarella R, et al. Percutaneous ethanol injection may be a definitive treatment for symptomatic thyroid cystic nodules not treatable by surgery: five-year follow-up study. *Thyroid.* 1999;9:763-767. [EL 3]
279. Bennedbaek FN, Hegedüs L. Treatment of recurrent thyroid cysts with ethanol: a randomized double-blind controlled trial. *J Clin Endocrinol Metab.* 2003;88:5773-5777. [EL 1]
280. Lippi F, Ferrari C, Manetti L, et al. Treatment of solitary autonomous thyroid nodules by percutaneous ethanol injection: results of an Italian multicenter study. The Multicenter Study Group. *J Clin Endocrinol Metab.* 1996;81:3261-3264. [EL 3]
281. Zingrillo M, Collura D, Ghiggi MR, Nirchio V, Trischitta V. Treatment of large cold benign thyroid nodules not eligible for surgery with percutaneous ethanol injection. *J Clin Endocrinol Metab.* 1998;83:3905-3907. [EL 3]
282. Bennedbaek FN, Nielsen LK, Hegedüs L. Effect of percutaneous ethanol injection therapy versus suppressive doses of L-thyroxine on benign solitary solid cold thyroid nodules: a randomized trial. *J Clin Endocrinol Metab.* 1998;83:830-835. [EL 1]
283. Pacella CM, Bizzarri G, Guglielmi R, et al. Thyroid tissue: US-guided percutaneous interstitial laser ablation feasibility study. *Radiology.* 2000;217:673-677. [EL 3]
284. Dossing H, Bennedbaek FN, Hegedüs L. Effect of ultrasound-guided interstitial laser photocoagulation on benign solitary solid cold thyroid nodules: a randomised study. *Eur J Endocrinol.* 2005;152:341-345. [EL 2]
285. Dossing H, Bennedbaek FN, Hegedüs L. Effect of ultrasound-guided interstitial laser photocoagulation on benign solitary solid cold thyroid nodules: one versus three treatments. *Thyroid.* 2006;16:763-768. [EL 3]
286. Papini E, Rago T, Gambelungho G, et al. Long-term efficacy of ultrasound-guided laser ablation for benign solid thyroid nodules: results of a three-year multicenter prospective randomized trial. *J Clin Endocrinol Metab.* 2014;99:3653-3659. [EL 1]
287. Papini E, Guglielmi R, Bizzarri G, et al. Treatment of benign cold thyroid nodules: a randomized clinical trial of percutaneous laser ablation versus levothyroxine therapy or follow-up. *Thyroid.* 2007;17:229-235. [EL 1]
288. Dossing H, Bennedbaek FN, Hegedüs L. Long-term outcome following interstitial laser photocoagulation of benign cold thyroid nodules. *Eur J Endocrinol.* 2011;165:123-128. [EL 2]
289. Baek JH, Lee JH, Valcavi R, Pacella CM, Rhim H, Na DG. Thermal ablation for benign thyroid nodules: radiofrequency and laser. *Korean J Radiol.* 2011;12:525-540. [EL 4]
290. Deandrea M, Limone P, Basso E, et al. US-guided percutaneous radiofrequency thermal ablation for the treatment of solid benign hyperfunctioning or compressive thyroid nodules. *Ultrasound Med Biol.* 2008;34:784-791. [EL 3]
291. Spiezia S, Garberoglio R, Milone F, et al. Thyroid nodules and related symptoms are stably controlled two years after radiofrequency thermal ablation. *Thyroid.* 2009;19:219-225. [EL 2]
292. Baek JH, Moon WJ, Kim YS, Lee JH, Lee D. Radiofrequency ablation for the treatment of autonomously functioning thyroid nodules. *World J Surg.* 2009;33:1971-1977. [EL 3]
293. Fuller CW, Nguyen SA, Lohia S, Gillespie MB. Radiofrequency ablation for treatment of benign thyroid nodules: systematic review. *Laryngoscope.* 2014;124:346-353. [EL 1]
294. Ha EJ, Baek JH, Kim KW, et al. Comparative efficacy of radiofrequency and laser ablation for the treatment of benign thyroid nodules: systematic review including traditional pooling and bayesian network meta-analysis. *J Clin Endocrinol Metab.* 2015;100:1903-1911. [EL 1]
- 294b. Pacella CM, Mauri G, Achille G, et al. Outcomes and Risk Factors for Complications of Laser Ablation for Thyroid Nodules. A Multicenter Study on 1531 Patients. *J Clin Endocrinol Metab.* 2015;100:3903-3910. [EL 3]

295. **Bonnema SJ, Hegedüs L.** Radioiodine therapy in benign thyroid diseases: effects, side effects, and factors affecting therapeutic outcome. *Endocr Rev.* 2012;33:920-980. [EL 4]
296. **Meier DA, Brill DR, Becker DV, et al.** Procedure guideline for therapy of thyroid disease with (131)iodine. *J Nucl Med.* 2002;43:856-861. [EL 4-guidelines]
297. **Nygaard B, Hegedüs L, Nielsen KG, Ulriksen P, Hansen JM.** Long-term effect of radioactive iodine on thyroid function and size in patients with solitary autonomously functioning toxic thyroid nodules. *Clin Endocrinol (Oxf).* 1999;50:197-202. [EL 3]
298. **Dietlein M, Dressler J, Grunwald F, et al.** Guideline for radioiodine therapy for benign thyroid diseases (version 4) [in German]. *Nuklearmedizin.* 2007;46:220-223. [EL 4-guidelines]
299. **Reiners C, Schneider P.** Radioiodine therapy of thyroid autonomy. *Eur J Nucl Med Mol Imaging.* 2002;29 Suppl 2:S471-S478. [EL 3]
300. **Nygaard B, Hegedüs L, Ulriksen P, Nielsen KG, Hansen JM.** Radioiodine therapy for multinodular toxic goiter. *Arch Intern Med.* 1999;159:1364-1368. [EL 2]
301. **Metso S, Jaatinen P, Huhtala H, Auvinen A, Oksala H, Salmi J.** Increased cardiovascular and cancer mortality after radioiodine treatment for hyperthyroidism. *J Clin Endocrinol Metab.* 2007;92:2190-2196. Erratum in: *J Clin Endocrinol Metab.* 2007;92:4008. [EL 2]
302. **Ron E, Doody MM, Becker DV, et al.** Cancer mortality following treatment for adult hyperthyroidism. Cooperative Thyrotoxicosis Therapy Follow-up Study Group. *JAMA.* 1998;280:347-355. [EL 3]
303. **Brandt F, Thvilum M, Almind D, et al.** Morbidity before and after the diagnosis of hyperthyroidism: a nationwide register-based study. *PLoS One.* 2013;8:e66711. [EL 2]
304. **Ceccarelli C, Bencivelli W, Vitti P, Grasso L, Pinchera A.** Outcome of radioiodine-131 therapy in hyperfunctioning thyroid nodules: a 20 years' retrospective study. *Clin Endocrinol (Oxf).* 2005;62:331-335. [EL 3]
305. **Nygaard B, Faber J, Veje A, Hegedüs L, Hansen JM.** Transition of nodular toxic goiter to autoimmune hyperthyroidism triggered by 131I therapy. *Thyroid.* 1999;9:477-481. [EL 3]
306. **Nygaard B, Knudsen JH, Hegedüs L, Scient AV, Hansen JE.** Thyrotropin receptor antibodies and Graves' disease, a side-effect of 131I treatment in patients with nontoxic goiter. *J Clin Endocrinol Metab.* 1997;82:2926-2930. [EL 3]
307. **Wallaschowski H, Muller D, Georgi P, Paschke R.** Induction of TSH-receptor antibodies in patients with toxic multinodular goitre by radioiodine treatment. *Horm Metab Res.* 2002;34:36-39. [EL 3]
308. **Bonnema SJ, Bennedbaek FN, Veje A, Marving J, Hegedüs L.** Propylthiouracil before 131I therapy of hyperthyroid diseases: effect on cure rate evaluated by a randomized clinical trial. *J Clin Endocrinol Metab.* 2004;89:4439-4444. [EL 2]
309. **Walter MA, Briel M, Christ-Crain M, et al.** Effects of antithyroid drugs on radioiodine treatment: systematic review and meta-analysis of randomised controlled trials. *BMJ.* 2007;334:514. [EL 1]
310. **Namwongprom S, Unachak K, Dejkhamron P, Ua-apisitwong S, Ekmahachai M.** Radioactive iodine for thyrotoxicosis in childhood and adolescence: treatment and outcomes. *J Clin Res Pediatr Endocrinol.* 2013; 5:95-97. [EL 2]
311. **Hegedüs L, Hansen BM, Knudsen N, Hansen JM.** Reduction of size of thyroid with radioactive iodine in multinodular non-toxic goitre. *BMJ.* 1988;297:661-662. [EL 3]
312. **Bonnema SJ, Fast S, Hegedüs L.** The role of radioiodine therapy in benign nodular goitre. *Best Pract Res Clin Endocrinol Metab.* 2014;28:619-631. [EL 4]
313. **Nygaard B, Hegedüs L, Gervil M, Hjalgrim H, Sørensen P, Hansen JM.** Radioiodine treatment of multinodular non-toxic goitre. *BMJ.* 1993;307:828-832. [EL 3]
314. **Wesche MF, Tiel-V Buul MM, Lips P, Smits NJ, Wiersinga WM.** A randomized trial comparing levothyroxine with radioactive iodine in the treatment of sporadic nontoxic goiter. *J Clin Endocrinol Metab.* 2001;86:998-1005. [EL 1]
315. **Weetman AP.** Radioiodine treatment for benign thyroid diseases. *Clin Endocrinol (Oxf).* 2007;66:757-764. [EL 4-review]
316. **Bonnema SJ, Bertelsen H, Mortensen J, et al.** The feasibility of high dose iodine 131 treatment as an alternative to surgery in patients with a very large goiter: effect on thyroid function and size and pulmonary function. *J Clin Endocrinol Metab.* 1999;84:3636-3641. [EL 4]
317. **Huysmans DA, Hermus AR, Corstens FH, Barentsz JO, Kloppenborg PW.** Large, compressive goiters treated with radioiodine. *Ann Intern Med.* 1994;121:757-762. [EL 3]
318. **Jarlov AE, Hegedüs L, Kristensen LO, Nygaard B, Hansen JM.** Is calculation of the dose in radioiodine therapy of hyperthyroidism worthwhile? *Clin Endocrinol (Oxf).* 1995;43:325-329. [EL 3]
319. **Sørensen JR, Hegedüs L, Kruse-Andersen S, Godballe C, Bonnema SJ.** The impact of goitre and its treatment on the trachea, airflow, oesophagus and swallowing function: a systematic review. *Best Pract Res Clin Endocrinol Metab.* 2014;28:481-494. [EL 2]
320. **Watt T, Cramon P, Hegedüs L, et al.** The thyroid-related quality of life measure ThyPRO has good responsiveness and ability to detect relevant treatment effects. *J Clin Endocrinol Metab.* 2014;99:3708-3717. [EL 2]
321. **Cramon P, Bonnema SJ, Bjorner JB, et al.** Quality of life in patients with benign nontoxic goiter: impact of disease and treatment response, and comparison with the general population. *Thyroid.* 2015;25:284-291. [EL 2]
322. **Watt T, Cramon P, Frenzl DM, Ware JE Jr, ThyQoL Group.** Assessing health-related quality of life in patients with benign non-toxic goitre. *Best Pract Res Clin Endocrinol Metab.* 2014;28:559-575. [EL 4]
323. **Fast S, Nielsen VE, Grupe P, et al.** Prestimulation with recombinant human thyrotropin (rhTSH) improves the long-term outcome of radioiodine therapy for multinodular nontoxic goiter. *J Clin Endocrinol Metab.* 2012;97: 2653-2660. [EL 1]
324. **Fast S, Nielsen VE, Bonnema SJ, Hegedüs L.** Time to reconsider nonsurgical therapy of benign non-toxic multinodular goitre: focus on recombinant human TSH augmented radioiodine therapy. *Eur J Endocrinol.* 2009;160: 517-528. [EL 4-review]
325. **Nielsen VE, Bonnema SJ, Boel-Jørgensen H, Grupe P, Hegedüs L.** Stimulation with 0.3-mg recombinant human thyrotropin prior to iodine 131 therapy to improve the size reduction of benign nontoxic nodular goiter: a prospective randomized double-blind trial. *Arch Intern Med.* 2006;166:1476-1482. [EL 1]

326. **Silva MN, Rubio IG, Romao R, et al.** Administration of a single dose of recombinant human thyrotrophin enhances the efficacy of radioiodine treatment of large compressive multinodular goitres. *Clin Endocrinol (Oxf)*. 2004;60:300-308. [EL 3]
327. **Barca MF, Gruppi C, Oliveira MT, et al.** Cardiovascular assessment of hyperthyroid patients with multinodular goiter before and after radioiodine treatment preceded by stimulation with recombinant human TSH. *Endocrine*. 2007;32:175-181. [EL 3]
328. **Nielsen VE, Bonnema SJ, Hegedüs L.** Transient goiter enlargement after administration of 0.3 mg of recombinant human thyrotrophin in patients with benign nontoxic nodular goiter: a randomized, double-blind, crossover trial. *J Clin Endocrinol Metab*. 2006;91:1317-1322. [EL 1]
329. **Pena S, Arum S, Cross M, et al.** 123I thyroid uptake and thyroid size at 24, 48, and 72 hours after the administration of recombinant human thyroid-stimulating hormone to normal volunteers. *J Clin Endocrinol Metab*. 2006;91:506-510. [EL 3]
330. **Fast S, Hegedüs L, Pacini F, et al.** Long-term efficacy of modified-release recombinant human thyrotrophin augmented radioiodine therapy for benign multinodular goiter: results from a multicenter, international, randomized, placebo-controlled, dose-selection study. *Thyroid*. 2014;24:727-735. [EL 1]
331. **Fast S, Nielsen VE, Grupe P, Bonnema SJ, Hegedüs L.** Optimizing 131I uptake after rhTSH stimulation in patients with nontoxic multinodular goiter: evidence from a prospective, randomized, double-blind study. *J Nucl Med*. 2009;50:732-737. [EL 1]
332. **Graf H, Fast S, Pacini F, et al.** Modified-release recombinant human TSH (MRrhTSH) augments the effect of (131)I therapy in benign multinodular goiter: results from a multicenter international, randomized, placebo-controlled study. *J Clin Endocrinol Metab*. 2011;96:1368-1376. [EL 1]
333. **Rosario PW.** Thyroid nodules with atypia or follicular lesions of undetermined significance (Bethesda Category III): importance of ultrasonography and cytological subcategory. *Thyroid*. 2014;24:1115-1120. [EL 2]
334. **Baloch Z, LiVolsi VA, Jain P, et al.** Role of repeat fine-needle aspiration biopsy (FNAB) in the management of thyroid nodules. *Diagn Cytopathol*. 2003;29:203-206. [EL 2]
335. **Na DG, Kim JH, Sung JY, et al.** Core-needle biopsy is more useful than repeat fine-needle aspiration in thyroid nodules read as nondiagnostic or atypia of undetermined significance by the Bethesda system for reporting thyroid cytopathology. *Thyroid*. 2012;22:468-475. [EL 2]
336. **McIver B, Castro MR, Morris JC, et al.** An independent study of a gene expression classifier (Afirma) in the evaluation of cytologically indeterminate thyroid nodules. *J Clin Endocrinol Metab*. 2014;99:4069-4077. [EL 2]
337. **NCCN categories of evidence and consensus [Internet].** National Comprehensive Cancer Network: c2012. Available at: [http://www.nccn.org/professionals/physician\\_gls/categories\\_of\\_consensus.asp](http://www.nccn.org/professionals/physician_gls/categories_of_consensus.asp). Accessed April 29, 2015. [EL 4-guidelines]
338. **Haymart MR, Greenblatt DY, Elson DF, Chen H.** The role of intraoperative frozen section if suspicious for papillary thyroid cancer. *Thyroid*. 2008;18:419-423. [EL 3]
339. **Cobin RH, Gharib H, Bergman DA, et al.** AACE/AAES medical/surgical guidelines for clinical practice: management of thyroid carcinoma. American Association of Clinical Endocrinologists. American College of Endocrinology. *Endocr Pract*. 2001;7:202-220. Erratum in: *Endocr Pract*. 2008 Sep;14(6):802-803. Multiple author names added. [EL 4-guidelines]
340. **Pacini F, Schlumberger M, Dralle H, et al.** European consensus for the management of patients with differentiated thyroid carcinoma of the follicular epithelium. *Eur J Endocrinol*. 2006;154:787-803. Erratum in: *Eur J Endocrinol*. 2006;155:385. [EL 4-consensus]
341. **Abalovich M, Amino N, Barbour LA, et al.** Management of thyroid dysfunction during pregnancy and postpartum: an Endocrine Society Clinical Practice Guideline. *J Clin Endocrinol Metab*. 2007;92 8 Suppl:S1-47. [EL 4-guidelines]
342. **Baloch ZW, Barroeta JE, Walsh J, et al.** Utility of thyroglobulin measurement in fine-needle aspiration biopsy specimens of lymph nodes in the diagnosis of recurrent thyroid carcinoma. *Cytojournal*. 2008;5:1. [EL 4]
343. **Ito Y, Miyauchi A.** Nonoperative management of low-risk differentiated thyroid carcinoma. *Curr Opin Oncol*. 2015;27:15-20. [EL 4-review]
344. **Freudenberg LS, Antoch G, Jentzen W, et al.** Value of (124)I-PET/CT in staging of patients with differentiated thyroid cancer. *Eur Radiol*. 2004;14:2092-1098. [EL 3]
345. **Papini E, Negro R, Pinchera A, et al.** Thyroid nodule and differentiated thyroid cancer management in pregnancy. An Italian Association of Clinical Endocrinologists (AME) and Italian Thyroid Association (AIT) Joint Statement for Clinical Practice. *J Endocrinol Invest*. 2010;33:579-586. [EL 4]
346. **Kung AW, Chau MT, Lao TT, Tam SC, Low LC.** The effect of pregnancy on thyroid nodule formation. *J Clin Endocrinol Metab*. 2002;87:1010-1014. [EL 2]
347. **Rosen IB, Korman M, Walfish PG.** Thyroid nodular disease in pregnancy: current diagnosis and management. *Clin Obstet Gynecol*. 1997;40:81-89. [EL 4]
348. **Marley EF, Oertel YC.** Fine-needle aspiration of thyroid lesions in 57 pregnant and postpartum women. *Diagn Cytopathol*. 1997;16:122-125. [EL 3]
349. **Moosa M, Mazzaferrri EL.** Outcome of differentiated thyroid cancer diagnosed in pregnant women. *J Clin Endocrinol Metab*. 1997;82:2862-2866. [EL 3]
350. **Messuti I, Corvisieri S, Bardesono F, et al.** Impact of pregnancy on prognosis of differentiated thyroid cancer: clinical and molecular features. *Eur J Endocrinol*. 2014;170:659-666. [EL 2]
351. **Galofré JC, Riesco-Eizaguirre G, Alvarez-Escolá C; Grupo de Trabajo de Cáncer de Tiroides de la Sociedad Española de Endocrinología y Nutrición.** Clinical guidelines for management of thyroid nodule and cancer during pregnancy. *Endocrinol Nutr*. 2014 Mar;61:130-138. [EL 4]
352. **Vannucchi G, Perrino M, Rossi S, et al.** Clinical and molecular features of differentiated thyroid cancer diagnosed during pregnancy. *Eur J Endocrinol*. 2010;162:145-151. [EL 3]
353. **Rallison ML, Dobyns BM, Keating FR Jr, Rall JE, Tyler FH.** Thyroid nodularity in children. *JAMA*. 1975;233:1069-1072. [EL 4]
354. **Hung W.** Nodular thyroid disease and thyroid carcinoma. *Pediatr Ann*. 1992;21:50-57. [EL 4-review]
355. **Raab SS, Silverman JF, Elsheikh TM, Thomas PA, Wakely PE.** Pediatric thyroid nodules: disease demographics and clinical management as determined by fine needle aspiration biopsy. *Pediatrics*. 1995;95:46-49. [EL 3]

356. **Amrikachi M, Ponder TB, Wheeler TM, Smith D, Ramzy I.** Thyroid fine-needle aspiration biopsy in children and adolescents: experience with 218 aspirates. *Diagn Cytopathol.* 2005;32:189-192. [EL 3]
357. **Chang SH, Joo M, Kim H.** Fine needle aspiration biopsy of thyroid nodules in children and adolescents. *J Korean Med Sci.* 2006;21:469-473. [EL 3]
358. **Canadian Pediatric Thyroid Nodule (CaPTN) Study Group.** The Canadian pediatric thyroid nodule study: an evaluation of current management practices. *J Pediatr Surg.* 2008;43:826-830. [EL 4]
359. **Drozd VM, Lushchik ML, Polyanskaya ON, et al.** The usual ultrasonographic features of thyroid cancer are less frequent in small tumors that develop after a long latent period after the Chernobyl radiation release accident. *Thyroid.* 2009;19:725-734. [EL 2]
360. **Buryk MA, Simons JP, Picarsic J, et al.** Can malignant thyroid nodules be distinguished from benign thyroid nodules in children and adolescents by clinical characteristics? A review of 89 pediatric patients with thyroid nodules. *Thyroid.* 2015;25:392-400. [EL 2]
361. **Feinmesser R, Lubin E, Segal K, Noyek A.** Carcinoma of the thyroid in children: a review. *J Pediatr Endocrinol Metab.* 1997;10:561-568. [EL 4-review]
362. **Alessandri AJ, Goddard KJ, Blair GK, Fryer CJ, Schultz KR.** Age is the major determinant of recurrence in pediatric differentiated thyroid carcinoma. *Med Pediatr Oncol.* 2000;35:41-46. [EL 3]
363. **Niedziela M, Breborowicz D, Trejster E, Korman E.** Hot nodules in children and adolescents in western Poland from 1996 to 2000: clinical analysis of 31 patients. *J Pediatr Endocrinol Metab.* 2002;15:823-830. [EL 3]
364. **Haynes RB, Wilczynski N, McKibbin KA, Walker CJ, Sinclair JC.** Developing optimal search strategies for detecting clinically sound studies in MEDLINE. *J Am Med Inform Assoc.* 1994;1:447-458. [EL 4]
365. **Hunt DL, McKibbin KA.** Locating and appraising systematic reviews. *Ann Intern Med.* 1997;126:532-538. [EL 4]
366. **Mechanick JI, Bergman DA, Braithwaite SS, Palumbo PJ; American Association of Clinical Endocrinologists Ad Hoc Task Force for Standardized Production of Clinical Practice Guidelines.** American Association of Clinical Endocrinologists protocol for standardized production of clinical practice guidelines. *Endocr Pract.* 2004;10:353-361. Erratum in: *Endocr Pract.* 2008;14:802-803. Mechanick, Jeffrey I [added]; Bergman, Donald A [added]; Braithwaite, Susan Shapiro [added]; Palumbo, Pasquale J [added]. [EL 4-guidelines]
367. **Mechanick JI, Kushner RF, Sugerman HJ, et al.** American Association of Clinical Endocrinologists, The Obesity Society, and American Society for Metabolic & Bariatric Surgery Medical guidelines for clinical practice for the perioperative nutritional, metabolic, and non-surgical support of the bariatric surgery patient. *Endocr Pract.* 2008;14 Suppl 1:1-83. Erratum in: *Endocr Pract.* 2009;15:768. [EL 4]